



# University of HUDDERSFIELD

## University of Huddersfield Repository

Vanita, V., Hennies, Hans C., Singh, D., Nürnberg, P., Sperling, K. and Singh, J.R.

A novel mutation in GJA8 associated with autosomal dominant congenital cataract in a family of Indian origin

### Original Citation

Vanita, V., Hennies, Hans C., Singh, D., Nürnberg, P., Sperling, K. and Singh, J.R. (2006) A novel mutation in GJA8 associated with autosomal dominant congenital cataract in a family of Indian origin. *Molecular Vision*, 12:121. pp. 1217-1222. ISSN 1090-0535

This version is available at <http://eprints.hud.ac.uk/id/eprint/28811/>

The University Repository is a digital collection of the research output of the University, available on Open Access. Copyright and Moral Rights for the items on this site are retained by the individual author and/or other copyright owners. Users may access full items free of charge; copies of full text items generally can be reproduced, displayed or performed and given to third parties in any format or medium for personal research or study, educational or not-for-profit purposes without prior permission or charge, provided:

- The authors, title and full bibliographic details is credited in any copy;
- A hyperlink and/or URL is included for the original metadata page; and
- The content is not changed in any way.

For more information, including our policy and submission procedure, please contact the Repository Team at: [E.mailbox@hud.ac.uk](mailto:E.mailbox@hud.ac.uk).

<http://eprints.hud.ac.uk/>



# A novel mutation in *GJA8* associated with autosomal dominant congenital cataract in a family of Indian origin

Vanita Vanita<sup>1</sup>, Hans Christian Hennies<sup>2</sup>, Daljit Singh<sup>3</sup>, Peter Nürnberg<sup>2</sup>, Karl Sperling<sup>4</sup>, Jai Rup Singh<sup>1</sup>

<sup>1</sup>Centre for Genetic Disorders, Guru Nanak Dev University, Amritsar, India; <sup>2</sup>Cologne Center for Genomics and Institute for Genetics, University of Cologne, Cologne, Germany; <sup>3</sup>Dr. Daljit Singh Eye Hospital, Amritsar, India; <sup>4</sup>Institute of Human Genetics, Charité, University Medicine of Berlin, Berlin, Germany

**Purpose:** To identify the genetic defect in an autosomal dominant congenital cataract family, having 15 members in three generations, affected with bilateral cataract that gave the appearance of “full moon” with Y-sutural opacities.

**Methods:** A detailed family history and clinical data were recorded. A genome-wide scan by two point linkage analysis using nearly 400 microsatellite markers in combination with multipoint lod score and haplotype analysis was carried out. Mutation screening was performed in the candidate gene by bidirectional sequencing of amplified products.

**Results:** A maximum two point lod score of 5.45 at  $\theta=0.00$  was obtained with marker D1S534. Haplotype analysis placed the cataract locus to a 14.1 cM region between D1S221 and D1S498, in close proximity to the gene for the gap junction channel protein connexin 50 (*GJA8*) at 1q21. Mutation screening in *GJA8* identified a novel G>C transversion at nucleotide position c.235. This nucleotide change resulted in the substitution of highly conserved valine by leucine at codon 79 (V79L). This nucleotide substitution was neither seen in any unaffected member of the family nor in 180 unrelated control subjects (360 chromosomes) from same ethnic background tested by sequence analysis of *GJA8*.

**Conclusions:** The present study describes the mapping of a locus for congenital cataract that appeared like “full moon” with Y-sutural opacities at 1q21 and identifies a previously unreported mutation in *GJA8*. These findings thus expand the mutation spectrum of *GJA8*.

Congenital cataract, a clinically and genetically highly heterogeneous eye lens disorder, is one of the significant causes of visual impairment or childhood blindness. Inter- and intra familial phenotypic variation is quite significant in congenital cataract and various types and sub types have been reported [1-3]. Nearly one third of the cases exhibit a positive family history and autosomal dominant is the most frequent mode of inheritance [3,4]. At least 35 loci have been linked with various forms of congenital and developmental cataracts, and mutations in at least 15 genes have been identified for isolated congenital cataracts [5].

Connexins (Cx) encode gap junction channel proteins that mediate intercellular transport of small biomolecules like ions, metabolites, and secondary messengers of less than 1 kDa in various cell types [6-9]. At least twenty connexins, categorized into three families, with molecular mass ranging between 25-62 kDa, have been identified in humans [10]. Three connexins that belong to the  $\alpha$ -connexin family are expressed in the human lens: Cx43, encoded by *GJA1*, in the epithelial cells while Cx46 and Cx50, encoded by *GJA3* and *GJA8*, respectively, in the terminally differentiated fibers [11-13]. Cx46 and Cx50 are responsible for joining the lens cells into a functional syncytium. Lens fibers are connected to the epithelial cells via gap junctions and are dependent on metabolically active epithelium for maintaining intracellular ionic conditions,

necessary to prevent precipitation of crystallins and hence cataract formation [14]. At least nine mutations in Cx46 and six mutations in Cx50 have been reported for human cataractogenesis. Defects in Cx46 and Cx50 have also been reported to result in cataract in mice [15-20].

Lens sutures are the lines at anterior and posterior poles of the embryonic lens nucleus where growing secondary fiber cells from the equator migrate and meet. Sutures start to appear during the eighth or ninth week of fetal life. The addition of more cell layers, until birth, forms the suture plane with a symmetrical Y-pattern and a symmetrical inverted Y-pattern at the anterior and posterior portion of the lens, respectively [21]. Abnormal development of sutures has been reported in association with specific types of cataracts [22]. Sutural cataract may occur as an isolated type of cataract [23] or in association with opacities involving other lens regions as well [24,25].

We identified a three generation family having bilateral congenital cataract. The cataract phenotype appeared like a “full moon”. The opacities involved both the Y-sutures as well. A genome-wide scan by linkage analysis and haplotype analysis placed the cataract locus between markers D1S221 and D1S498 on chromosome 1q21, close to *GJA8*. Upon sequence analysis of *GJA8* we identified a heterozygous change resulting in the missense mutation valine to leucine at codon 79 (V79L). The change cosegregated completely with the disease phenotype, thus suggesting this as the disease causing mutation in the present family. This is a novel mutation not reported previously with congenital cataract.

Correspondence to: Dr. Vanita Vanita, Centre for Genetic Disorders, Guru Nanak Dev University, Amritsar-143005, Punjab, India; Phone: + 0183-2258802-09 Ext. 3277, 3279; FAX: + 0183-2258863 or 0183-2258820; email: vanita\_kumar@yahoo.com

**METHODS**

**Family description:** The proband, a 12-year-old child, was diagnosed as having bilateral cataract that gave the appearance of a “full moon” (Figure 1). Y-sutural opacities were also observed. The detailed family history revealed 15 living affected members in three generations (Figure 2). Detailed ophthalmic examination that included slit lamp examination and photography of affected lenses, carried out on 23 members of the family, confirmed 15 members affected with bilateral cataract and 8 individuals (including 3 spouses) as unaffected. Some affected individuals had cataract extraction in their early childhood.

**Phenotype description:** In the unoperated affected individuals, the cataract phenotype gave the appearance of a “full moon”. Opacities were also seen around the Y-sutures (Figure 1A). Apart from sutural opacities, the embryonal nucleus appeared clear and showed no opacities. Optical section of the lens revealed very fine white opacities in the fetal nucleus immediately surrounding the embryonal nucleus, giving it a granular appearance (Figure 1B).

**Genotyping and linkage analysis:** This study was approved by our institutional review board. Written informed consent was obtained from each individual studied. Blood was

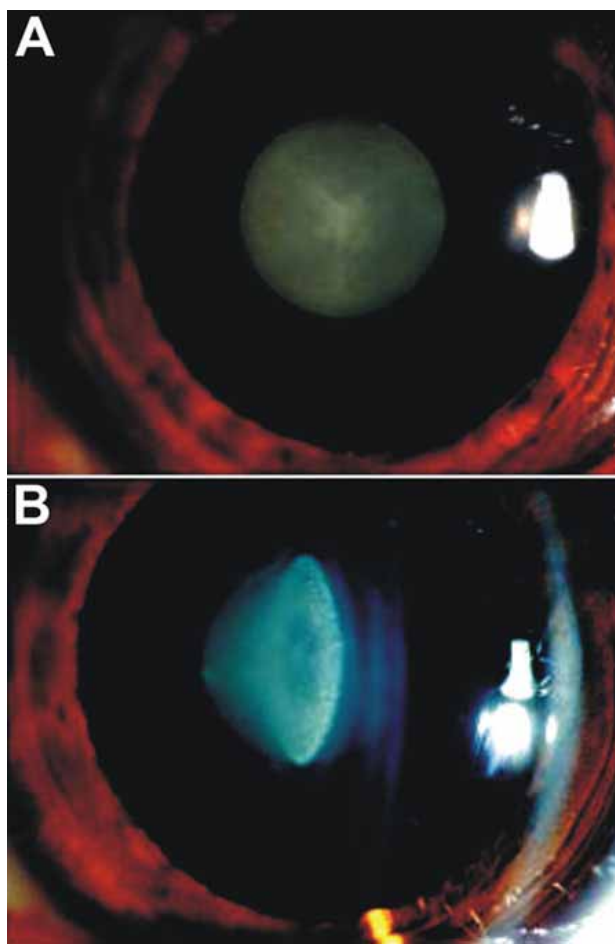


Figure 1. Lens photograph of a 12-year-old patient (IV-3). **A:** Cataract phenotype exhibits the appearance of full moon with both the Y-sutures being affected. **B:** Optical section showing lens opacities in patient IV-3. The optical section of lens showing absence of opacities in the embryonal region. The fetal nucleus surrounding the embryonal nucleus shows very fine white granular opacities.

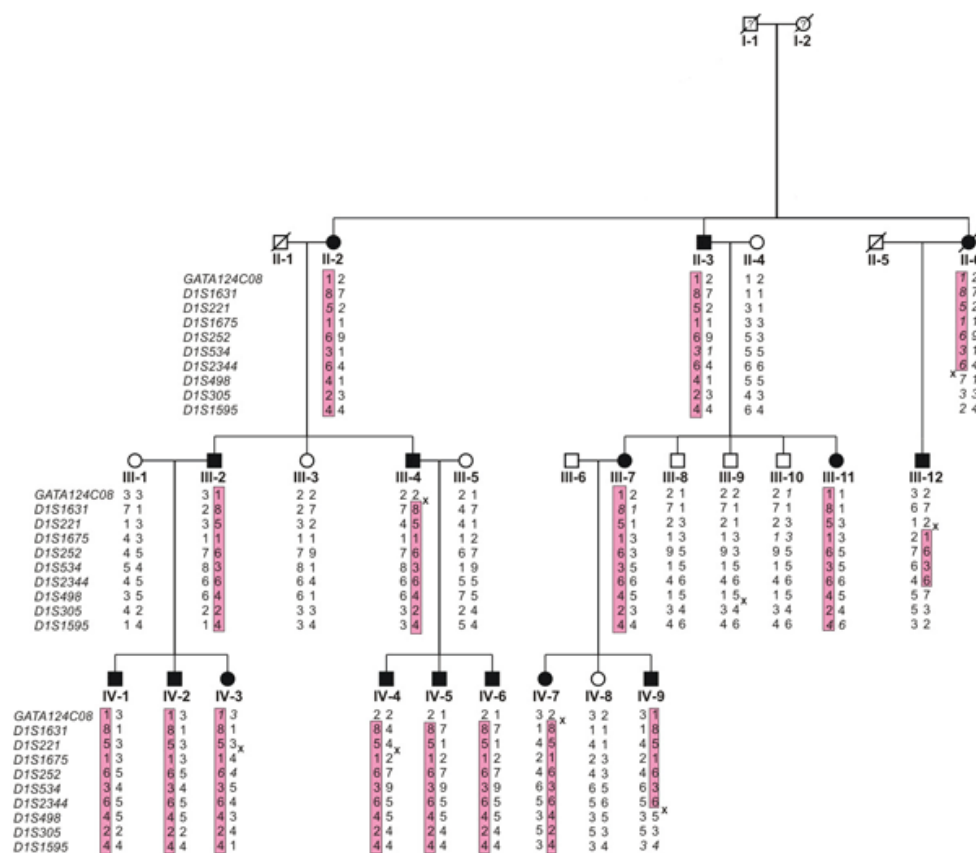


Figure 2. Haplotype analysis of the cataract family with chromosome 1 markers. Sequence of markers is from centromere to telomere. Haplotypes segregating with the disease are indicated in the shaded boxes. Inferred haplotypes are shown in italics. Recombination events seen in III-4, III-12, IV-7, and IV-9 place the disease gene locus between markers D1S221 and D1S498.

drawn and DNA isolated by standard methods. A genome-wide search with nearly 400 microsatellite markers (Genethon linkage map) [26] was performed on the DNA samples of all 23 ophthalmologically examined individuals following methods and conditions described elsewhere [23]. Autosomal dominant inheritance with a disease gene frequency of 0.0001 was assumed. A reduced penetrance of 98% and a phenocopy rate of 0.5% were considered. Recombination frequencies were considered equal between males and females. Two point and multipoint linkage analyses were carried out with the LINKAGE program package [27] and GeneHunter [28], respectively.

**Mutation analysis:** Primer sequences used to amplify the exonic region of *GJA8* (GenBank U34802 and P48165) were from Shiels et al. [29]. Genomic DNA from two affected and one unaffected individuals were amplified in a 25  $\mu$ l reaction volume following conditions described elsewhere [23]. PCR products were purified and sequenced bidirectionally following conditions as detailed elsewhere [30]. Sequencing results were assembled and analyzed using the SeqMan II program of the Lasergene package (DNA STAR Inc., Madison, WI).

## RESULTS

**Linkage analysis:** In a genome-wide scan using nearly 400 microsatellite markers, we obtained a positive two point lod score of 2.91 at  $\theta=0.000$  with marker D1S221. Further analysis with more markers in this region on chromosome 1 gave significant positive lod scores, indicative of linkage. A maximum two point lod score of 5.45 at  $\theta=0.000$  was obtained with marker D1S534. Multipoint analysis carried out with analyzed markers from this region also supported the linkage with the same maximum lod score of 5.45 at D1S534 (data not shown).

**Haplotype analysis:** Haplotypes were constructed for the markers analyzed on chromosome 1 (Figure 2). Recombination events were detected in four affected individuals (III-4, III-12, IV-7, and IV-9). Individuals III-4 and IV-7 showed a recombination event at the most proximal marker, GATA124C08. Individual III-12 was recombinant at markers proximal to D1S1675 as well distal to D1S2344, the latter recombination probably inherited from his mother (II-6). Individual IV-9 was also found to be recombinant at markers distal to D1S2344. Cosegregation was observed in all affected individuals for markers D1S1675 to D1S2344. The cataract locus was thus mapped to the 14.1 cM region between D1S221 and D1S498, which corresponds to a region on chromosome 1q21.1.

**Mutation screening:** Sequencing of the complete coding region of *GJA8* in two affected (II-2 and IV-7) and one unaffected individuals (III-3) showed a heterozygous change G>C (Figure 3) at position 235 (c.235G>C) from the transcription start site in patients. This was the only change seen in all the 15 affected individuals of this family. The alteration was neither seen in any unaffected family member nor in 180 unrelated control subjects (360 chromosomes) from the same Northern Indian population, tested by bidirectional sequence analysis (data not shown). This nucleotide substitution replaces

an evolutionarily highly conserved valine with leucine at amino acid position 79 (V79L) in the  $\alpha$ -helical transmembrane domain 2 (M2) of Cx50.

## DISCUSSION

The present study describes the identification of a novel V79L substitution in Cx50 segregating solely in 15 affected members of a three generation family, having “full moon”-like cataract with Y-sutural opacities. The observed V79L substitution lies within the second transmembrane domain (M2) of Cx50

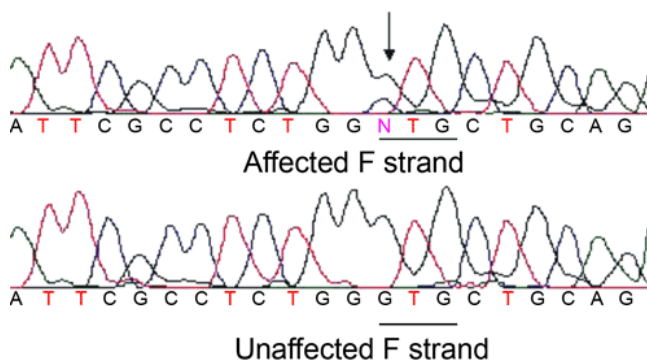


Figure 3. DNA sequence of a part of *GJA8* in an affected and unaffected individual. Electropherogram showing a part of the sequence of *GJA8* in an affected and an unaffected family member (forward strand; individuals II-2 and III-3, respectively). A heterozygous change G>C at the first base of codon 79 (GTG-C/GTG) resulting in substitution of valine 79 by leucine (V79L) in the affected individual's sequence is indicated by an arrow.

A		71	↓81	91
Homo sapiens	65	CYDEAFPISHIRLW	V	LQIIFVSTPSLMY
Pan troglodytes	65	CYDEAFPISHIRLW	V	LQIIFVSTPSLMY
Macaca mulatta	65	CYDEAFPISHIRLW	V	LQIIFVSTPSLMY
Rattus norvegicus	65	CYDEAFPISHIRLW	V	LQIIFVSTPSLMY
Mus musculus	65	CYDEAFPISHIRLW	V	LQIIFVSTPSLMY
Canis familiaris	65	CYDEAFPISHIRLW	V	LQIIFVSTPSLVY
Bos taurus	65	CYDEAFPISHIRLW	V	LQIIFVSTPSLVY
Gallus gallus	65	CYDEAFPISHIRLW	V	LQIIFVSTPSLVY
Danio rerio	65	CYDTFAPVSHLR	V	FQIVLVSTPSIFY

B		71	↓81	91
GJA8	65	CYDEAFPISHIRLW	V	LQIIFVSTPSLMY
GJA3	65	CYDRAFPISHIRFW	V	LQIIFVSTPTLIY
GJA5	65	CYDQAFPISHIRYW	V	LQIIFVSTPSLVY
CX62	65	CYDDAFPISLIRFW	V	LQIIFVSSPSLVY
GJA10	65	CYDQAFPISLIRYW	V	LQIVFVSSPSLVY
GJA1	65	CYDKSFPISHVRFW	V	LQIIFVSVPTLLY
GJA4	65	CYDQAFPISHIRYW	V	LQFLFVSTPTLVY
GJA7	64	CYDAFAPLSHVRFW	V	FQIILVATPSVMY
GJA9	66	CYDRAFPISHIRYW	V	FQIIMVCTPSLCF
GJA12	67	CYDAFAPLSHVRFW	V	FQIVVISTPSVMY

Figure 4. A multiple alignment of amino acid sequences of Cx50 in different species and in different human  $\alpha$ -type gap junction proteins. Alignment data indicate that valine at position 79 is highly conserved in different species (A) and in different  $\alpha$ -type gap junction proteins in humans (B).

and represents a conservative amino acid change as both valine and leucine belong to the same group of uncharged non-polar amino acids with an aliphatic functional group under physiological conditions. Valine-79 is well conserved in the second transmembrane domain of connexin 50 in different

species (Figure 4A) and also in different human  $\alpha$ -type gap junctional proteins (Figure 4B). The V79L mutation may influence the correct transport of proteins into the plasma membrane. Polyakov et al. [31] have also reported a conservative change Ile247Met in Cx50 in a Russian family with zonular

TABLE 1.

Amino acid change	Location/GJA8 domain	Cataract type	Phenotype description	Origin of Family	Reference
R23T	Cytoplasmic N-terminal	Congenital nuclear	Progressive, dense nuclear (fetal/embryonal)	Iranian	[39]
V44E	First transmembrane domain (M1)	Congenital cataract and microcornea	Total lens opacification	Indian	[40]
E48K	First extracellular loop (E1)	Zonular nuclear pulverulent	Non-progressive, fine dust-like opacities, more dense throughout the nucleus. Several cortical riders in the zonular region.	Pakistani	[41]
V79L	Second transmembrane domain (M2)	Full moon like with Y-sutural opacities	Stationary cataract both Y-sutures affected. No opacities in embryonal nucleus, fine granular white opacity outside the embryonal nucleus in the fetal nuclear region.	Indian	Present study
P88S	Second transmembrane domain (M2)	Zonular pulverulent	Non-progressive, innumerable powdery opacities located in the nuclear and lamellar zones. Affects both the embryonic and fetal nucleus: "total nuclear cataract."	English	[29]
R198Q	Second extracellular loop (E2)	Cataract and microcornea	Posterior subcapsular	Indian	[40]
I247M	Cytoplasmic C-terminus	Zonular pulverulent	Progressive, non homogeneous opacity consisting of opaque particles of different sizes, most of these very small, distributed unequally in a disc of 5 mm in diameter in the center of the lens. Also a slightly cloudy inhomogeneous area of 2 mm at posterior pole.	Russian	[31]

Mutation spectrum of Connexin 50 and cataract phenotypes in different congenital cataract families.



pulverulent cataract (Table 1). The mutation V79L identified by us lies very close to a previously reported mutation P88S, which is associated with autosomal dominant zonular pulverulent cataract in an English family (Table 1). Proline at codon 88 has a function in voltage gating of gap junctions in Cx26 [32]. The P88S mutant connexin abolishes gap junction channel function and acts in a dominant negative manner [33].

Mutations in Cx46 and Cx50 have been found in association with congenital cataracts in man and mice. In man previously at least six mutations have been reported in Cx50 (*GJA8*) in six different families (Table 1). Four of these families have been reported to have either a zonular or zonular pulverulent cataract (CZP1; OMIM 116200). Similarly, at least nine mutations have been reported in Cx46 (*GJA3*) at 13q11-q12, of which seven were associated with nuclear or zonular pulverulent cataract. Zonular pulverulent cataract, also known as Coppock cataract, was first described by Neetleship and Ogilvie [34] as pulverulent disc-like opacity involving the embryonal and fetal nucleus with many tiny white dots in the lamellar portion of the lens. It has also been referred to as "total nuclear" cataract [35]. It is larger, 4 mm in diameter, and differs from the Coppock-like cataract. The Coppock-like cataract is limited to the embryonic nucleus, is 2 mm in diameter [36], and has been reported to be caused by mutations in  $\gamma$ C- and  $\beta$ B2-crystallin genes [37,38]. The phenotype seen in our Indian family differs from the previously reported phenotypes associated with *GJA8*, as the Y-sutural opacities were present in all of the unoperated affected individuals. Upon optical section no opacity was seen in the embryonal nucleus and very fine opacities were observed in the fetal nucleus only.

So far, at least seven congenital cataract families have been linked with *GJA8* but significant inter-familial phenotypic variability has been observed in these cases (Table 1). Thus, it seems that in cataract, one major gene is involved but variants in other genes, involved in lens development, growth, and maintenance, might cause phenotypic variability.

In summary, we describe a novel heterozygous V79L mutation in Cx50 in an autosomal dominant congenital cataract family of Indian origin. As the phenotype observed in this family showed marked variability from the previously reported phenotypes linked with *GJA8*, the present findings further expand the genotypic-phenotypic heterogeneity of congenital cataract.

#### ACKNOWLEDGEMENTS

We wish to thank the patients and their relatives for their cooperation. This work was in part supported by grant number DBT/BT/IC/71/89/Pt from the Department of Biotechnology sanctioned to JRS, INI 331 from Bundesministerium für Bildung und Forschung to KS, SR/FT/L-91 from the Department of Science & Technology to VV, and by a grant in aid from the National Genome Research Network to HCH and to PN.

#### REFERENCES

1. Scott MH, Hejtmancik JF, Wozencraft LA, Reuter LM, Parks MM, Kaiser-Kupfer MI. Autosomal dominant congenital cataract. Interocular phenotypic variability. *Ophthalmology* 1994; 101:866-71.
2. Vanita. Genetical investigations in congenital cataract cases. 1998; Ph.D thesis, Guru Nanak Dev University, Amritsar, India.
3. Amaya L, Taylor D, Russell-Eggitt I, Nischal KK, Lengyel D. The morphology and natural history of childhood cataracts. *Surv Ophthalmol* 2003; 48:125-44.
4. Vanita, Singh JR, Singh D. Genetic and segregation analysis of congenital cataract in the Indian population. *Clin Genet* 1999; 56:389-93.
5. Zhang Q, Guo X, Xiao X, Yi J, Jia X, Hejtmancik JF. Clinical description and genome wide linkage study of Y-sutural cataract and myopia in a Chinese family. *Mol Vis* 2004; 10:890-900.
6. Kelsell DP, Dunlop J, Stevens HP, Lench NJ, Liang JN, Parry G, Mueller RF, Leigh IM. Connexin 26 mutations in hereditary non-syndromic sensorineural deafness. *Nature* 1997; 387:80-3.
7. Bergoffen J, Scherer SS, Wang S, Scott MO, Bone LJ, Paul DL, Chen K, Lensch MW, Chance PF, Fischbeck KH. Connexin mutations in X-linked Charcot-Marie-Tooth disease. *Science* 1993; 262:2039-42.
8. Richard G, White TW, Smith LE, Bailey RA, Compton JG, Paul DL, Bale SJ. Functional defects of Cx26 resulting from a heterozygous missense mutation in a family with dominant deaf-mutism and palmoplantar keratoderma. *Hum Genet* 1998; 103:393-9.
9. White TW, Bruzzone R, Wolfram S, Paul DL, Goodenough DA. Selective interactions among the multiple connexin proteins expressed in the vertebrate lens: the second extracellular domain is a determinant of compatibility between connexins. *J Cell Biol* 1994; 125:879-92.
10. White TW, Srinivas M, Ripps H, Trovato-Salinaro A, Condorelli DF, Bruzzone R. Virtual cloning, functional expression, and gating analysis of human connexin31.9. *Am J Physiol Cell Physiol* 2002; 283:C960-70.
11. Musil LS, Beyer EC, Goodenough DA. Expression of the gap junction protein connexin43 in embryonic chick lens: molecular cloning, ultrastructural localization, and post-translational phosphorylation. *J Membr Biol* 1990; 116:163-75.
12. Paul DL, Ebihara L, Takemoto LJ, Swenson KI, Goodenough DA. Connexin46, a novel lens gap junction protein, induces voltage-gated currents in nonjunctional plasma membrane of *Xenopus* oocytes. *J Cell Biol* 1991; 115:1077-89.
13. White TW, Bruzzone R, Goodenough DA, Paul DL. Mouse Cx50, a functional member of the connexin family of gap junction proteins, is the lens fiber protein MP70. *Mol Biol Cell* 1992; 3:711-20.
14. Simon AM, Goodenough DA. Diverse functions of vertebrate gap junctions. *Trends Cell Biol* 1998; 8:477-83.
15. Runge PE, Hawes NL, Heckenlively JR, Langley SH, Roderick TH. Autosomal dominant mouse cataract (Lop-10). Consistent differences of expression in heterozygotes. *Invest Ophthalmol Vis Sci* 1992; 33:3202-8.
16. Gong X, Li E, Klier G, Huang Q, Wu Y, Lei H, Kumar NM, Horwitz J, Gilula NB. Disruption of alpha3 connexin gene leads to proteolysis and cataractogenesis in mice. *Cell* 1997; 91:833-43.
17. Steele EC Jr, Lyon MF, Favor J, Guillot PV, Boyd Y, Church RL. A mutation in the connexin 50 (Cx50) gene is a candidate for the No2 mouse cataract. *Curr Eye Res* 1998; 17:883-9.
18. White TW, Goodenough DA, Paul DL. Targeted ablation of connexin50 in mice results in microphthalmia and zonular pulverulent cataracts. *J Cell Biol* 1998; 143:815-25.

19. Xu X, Ebihara L. Characterization of a mouse Cx50 mutation associated with the No2 mouse cataract. *Invest Ophthalmol Vis Sci* 1999; 40:1844-50.
20. Rong P, Wang X, Niesman I, Wu Y, Benedetti LE, Dunia I, Levy E, Gong X. Disruption of Gja8 (alpha8 connexin) in mice leads to microphthalmia associated with retardation of lens growth and lens fiber maturation. *Development* 2002; 129:167-74.
21. Jaffe NS, Horwitz J. Lens and cataract. In: Podos SM, Yanoff M, editors. *Text book of Ophthalmology*. Vol. 3. New York: Gower Medical Publishing; 1992. p. 1.7.
22. Kuszak JR, Zoltoski RK, Tiedemann CE. Development of lens sutures. *Int J Dev Biol* 2004; 48:889-902.
23. Vanita V, Hejtmancik JF, Hennies HC, Guleria K, Nürnberg P, Singh D, Sperling K, Singh JR. Sutural cataract associated with a mutation in the ferritin light chain gene (FTL) in a family of Indian origin. *Mol Vis* 2006; 12:93-9.
24. Vanita, Singh JR, Sarhadi VK, Singh D, Reis A, Rueschendorf F, Becker-Follmann J, Jung M, Sperling K. A novel form of “central pouchlike” cataract, with sutural opacities, maps to chromosome 15q21-22. *Am J Hum Genet* 2001; 68:509-14.
25. Vanita, Sarhadi V, Reis A, Jung M, Singh D, Sperling K, Singh JR, Burger J. A unique form of autosomal dominant cataract explained by gene conversion between beta-crystallin B2 and its pseudogene. *J Med Genet* 2001; 38:392-6.
26. Dib C, Faure S, Fizames C, Samson D, Drouot N, Vignal A, Millasseau P, Marc S, Hazan J, Seboun E, Lathrop M, Gyapay G, Morissette J, Weissenbach J. A comprehensive genetic map of the human genome based on 5,264 microsatellites. *Nature* 1996; 380:152-4.
27. Lathrop GM, Lalouel JM. Easy calculations of lod scores and genetic risks on small computers. *Am J Hum Genet* 1984; 36:460-5.
28. Kruglyak L, Daly MJ, Reeve-Daly MP, Lander ES. Parametric and nonparametric linkage analysis: a unified multipoint approach. *Am J Hum Genet* 1996; 58:1347-63.
29. Shiels A, Mackay D, Ionides A, Berry V, Moore A, Bhattacharya S. A missense mutation in the human connexin50 gene (GJA8) underlies autosomal dominant “zonular pulverulent” cataract, on chromosome 1q. *Am J Hum Genet* 1998; 62:526-32.
30. Vanita V, Singh D, Robinson PN, Sperling K, Singh JR. A novel mutation in the DNA-binding domain of MAF at 16q23.1 associated with autosomal dominant “cerulean cataract” in an Indian family. *Am J Med Genet A* 2006; 140:558-66.
31. Polyakov AV, Shagina IA, Khlebnikova OV, Evgrafov OV. Mutation in the connexin 50 gene (GJA8) in a Russian family with zonular pulverulent cataract. *Clin Genet* 2001; 60:476-8.
32. Suchyna TM, Xu LX, Gao F, Fourtner CR, Nicholson BJ. Identification of a proline residue as a transduction element involved in voltage gating of gap junctions. *Nature* 1993; 365:847-9.
33. Pal JD, Berthoud VM, Beyer EC, Mackay D, Shiels A, Ebihara L. Molecular mechanism underlying a Cx50-linked congenital cataract. *Am J Physiol* 1999; 276:C1443-6. Erratum in: *Am J Physiol* 1999; 277:section C.
34. Nettleship E, Ogilvie FM. A peculiar form of hereditary congenital cataract. *Trans Ophthalmol Soc* 1906; 26:191-207.
35. Renwick JH. Eyes on chromosomes. *J Med Genet* 1970; 7:239-43.
36. Lubsen NH, Renwick JH, Tsui LC, Breitman ML, Schoenmakers JG. A locus for a human hereditary cataract is closely linked to the gamma-crystallin gene family. *Proc Natl Acad Sci U S A* 1987; 84:489-92.
37. Heon E, Priston M, Schorderet DF, Billingsley GD, Girard PO, Lubsen N, Munier FL. The gamma-crystallins and human cataracts: a puzzle made clearer. *Am J Hum Genet* 1999; 65:1261-7.
38. Gill D, Klose R, Munier FL, McFadden M, Priston M, Billingsley G, Ducrey N, Schorderet DF, Heon E. Genetic heterogeneity of the Coppock-like cataract: a mutation in CRYBB2 on chromosome 22q11.2. *Invest Ophthalmol Vis Sci* 2000; 41:159-65.
39. Willoughby CE, Arab S, Gandhi R, Zeinali S, Arab S, Luk D, Billingsley G, Munier FL, Heon E. A novel GJA8 mutation in an Iranian family with progressive autosomal dominant congenital nuclear cataract. *J Med Genet* 2003; 40:e124.
40. Devi RR, Vijayalakshmi P. Novel mutations in GJA8 associated with autosomal dominant congenital cataract and microcornea. *Mol Vis* 2006; 12:190-5.
41. Berry V, Mackay D, Khaliq S, Francis PJ, Hameed A, Anwar K, Mehdi SQ, Newbold RJ, Ionides A, Shiels A, Moore T, Bhattacharya SS. Connexin 50 mutation in a family with congenital “zonular nuclear” pulverulent cataract of Pakistani origin. *Hum Genet* 1999; 105:168-70.