



# University of HUDDERSFIELD

## University of Huddersfield Repository

Ousey, Karen and Cutting, Keith

Wound healing and hyper-hydration - a counter intuitive model

### Original Citation

Ousey, Karen and Cutting, Keith (2016) Wound healing and hyper-hydration - a counter intuitive model. *Journal of wound care*, 25 (2). pp. 68-75. ISSN 0969-0700

This version is available at <http://eprints.hud.ac.uk/id/eprint/27031/>

The University Repository is a digital collection of the research output of the University, available on Open Access. Copyright and Moral Rights for the items on this site are retained by the individual author and/or other copyright owners. Users may access full items free of charge; copies of full text items generally can be reproduced, displayed or performed and given to third parties in any format or medium for personal research or study, educational or not-for-profit purposes without prior permission or charge, provided:

- The authors, title and full bibliographic details is credited in any copy;
- A hyperlink and/or URL is included for the original metadata page; and
- The content is not changed in any way.

For more information, including our policy and submission procedure, please contact the Repository Team at: [E.mailbox@hud.ac.uk](mailto:E.mailbox@hud.ac.uk).

<http://eprints.hud.ac.uk/>

## Wound healing and hyper-hydration - a counter intuitive model

### Abstract:

Winters seminal work in the 1960s relating to providing an optimal level of moisture to aid wound healing (granulation and re-epithelialisation) has been the single most effective advance in wound care over many decades. As such the development of advanced wound dressings that manage the fluidic wound environment have provided significant benefits in terms of healing to both patient and clinician. Although moist wound healing provides the guiding management principle confusion may arise between what is deemed to be an adequate level of tissue hydration and the risk of developing maceration. In addition, the counter-intuitive model 'hyper-hydration' of tissue appears to frustrate the moist wound healing approach and advocate a course of intervention whereby tissue is hydrated beyond what is a normally acceptable therapeutic level. This paper discusses tissue hydration, the cause and effect of maceration and distinguishes these from hyper-hydration of tissue. The rationale is to provide the clinician with a knowledge base that allows optimisation of treatment and outcomes and explains the reasoning behind wound healing using hyper-hydration.

**Key Words:** Hyper-hydration, Hydration, Moisture Balance, Maceration, Skin, Wound Dressings

### Introduction:

A homeostatic moist wound environment is generally accepted as beneficial to the healing process and co-exists with an adequately hydrated wound. Conversely, maceration of the peri-wound skin is considered to have a far-reaching and negative influence which impacts adversely on the patient, clinician (1, 2) as a result of putative excessive hydration. A lack of clarity exists in respect of the optimal level of hydration required to support healing and, in like manner, the origin of fear associated with excessive hydration of the peri-wound skin (maceration) appears to be founded on anecdotal evidence at best. (2) This paper endeavours to clarify understanding of tissue hydration in relation to wound healing, maceration and to rationalise the counter intuitive model of healing through hyper-hydration. Developing understanding, based on the available evidence, of wound/soft tissue hydration, peri-wound maceration and the nuances of hyper-hydration has the potential to improve not only patient outcomes but also clinicians' appreciation of topical wound dressings and the role they have to play in support of healing.

**Moisture and wound healing:** Healing of the skin consists of four overlapping and integrated phases haemostasis, inflammation, proliferation and remodelling.(3) This initial haemostatic response is characterised by platelet activation and coagulation, ensuring that blood loss is minimised. The inflammatory phase consists of an influx of inflammatory cells and mediators that help to prevent infection through the open wound. This is then followed by periods of cellular proliferation, extracellular matrix (ECM) deposition and finally remodelling which leads to scar formation.(3) Underpinning these processes is angiogenesis that generally occurs in the proliferative phase of healing and leads to a temporary increase in the number of blood vessels at the site of injury.(4) Although remodelling is regarded as the final phase of the repair process it is important to remember that remodelling of tissue takes place throughout the repair process and is not isolated to the post-closure phase. (3)

Wound hydration has been the basis of modern wound care since the seminal papers of Winter (5-8) in the 1960s. Since then scientific research *in vitro* and *in vivo* has supported this original premise (9-15) and moist wound healing has become the recognised tenet of clinicians working in the wound care field. (16) Specifically some studies have highlighted that moisture retained over the wound prevents desiccation of the wound surface and/or deeper tissues allowing for an unimpeded migration of epithelial cells over the wound surface. (5, 17-19) Cytokines and growth factors are also enabled to exert their beneficial effect on wound contracture and re-epithelialization.(20, 21) There is improved cosmesis, the provision of an environment that supports autolysis(22, 23) and a decrease in pain experienced e.g. in split thickness graft donor sites.(24) The many benefits that may result from maintaining a moist healing environment are recorded in Table 1. Good hydration (of the wound) has been described as the single most important external factor responsible for optimal wound healing.(20)

### **Tissue hydration**

All biological processes require water and is essential for maintaining homeostasis. It is a universal solvent, a mediator of life's chemical reactions, and has a structure unlike that of any other liquid. (25) From the time that primeval species ventured from the oceans to live on land, a major key to survival has been the maintenance of hydration. Without water, humans can survive only for days. In man, water content ranges from 75% body weight in infants, to 55% in elderly (26) with the skin having a water content of approximately 30%. The outermost layer of the epidermis, the stratum corneum, prevents water loss. It forms a water-impermeable barrier. Any structural defect of its integrity will result in uncontrolled water loss such as in ruptured blisters or more dramatically in

burns. The noticeable water “loss” like sweating is the result of active water transport in sweat glands regulated by ion and water channels. Dermal interstitial fluid is mostly taken up by glycosaminoglycans e.g. hyaluronan that has the capacity to displace a large volume of water. (27) The skin therefore provides an interface between the body and the environment that helps to restrict water loss and prevents the entry of potentially harmful environmental substances and microorganisms. (28, 29)

In intact skin, the opposing forces of interstitial fluid pressure and capillary filtration pressure together with the rate of lymphatic drainage control fluid inflow from the local vasculature to the extracellular matrix (ECM)(30) and thus maintain tissue hydration. However, when wounding occurs this mechanism is compromised and fluid inflow from the blood vessels increases due to vascular leakiness triggered by inflammation and is observed on the wound surface as exudate. Not all of the fluid that results from this decrease in interstitial fluid pressure resides on the wound surface as some ECM components such as hyaluronan absorb and hold this fluid at a capacity greater than that achieved by the skin.(27)

A number of definitions of hydration exist, but in relation to soft tissue, the most appropriate appears to be *“the process of providing an adequate amount of liquid to bodily tissues”*.(31) Naturally, the question arises – what is adequate?

### **Hyper-hydration of the skin**

Following prolonged exposure to water, swelling and absorption occur in the dead corneocytes in the outermost layer of the stratum corneum.(32) These cells are stacked in layers like bricks and their swelling is the key process by which their permeability and the mechanics of fluid interactions within the skin is controlled. (32) These cells contain a network of keratin filaments that interlock to form a three-dimensional lattice - which can increase its volume by five times when the strands stretch out. (32) The interplay of these opposing forces ensures that the skin can only absorb a certain amount of water, limited by the skin's physical structure.(32)

Immersion in a moist/wet environment for prolonged periods of time results in the skin becoming white and wrinkly (Figure 1). It is thought that this wrinkling response may provide an evolutionary benefit in terms of providing improved grip in wet conditions (33) and a better grasp of wet objects.(34) This wrinkling mechanism was investigated by Lewis and Pickering (1936) who suggested that the phenomenon was not solely related to water absorption but that the nervous

system was also implicated.(35) Recent findings support this view and indicate that sympathetic innervation is important in water-immersion skin wrinkling.(36)

Some authors have shown that prolonged exposure to water can lead to dermatitis(37) (38) but that exposure of the skin to water for short periods of time is generally deemed to be innocuous.(39) This latter finding is supported by a study that evaluated the effect of continuous exposure of human skin to water for 72hr and 144 hr. The results showed that only a mild, transient dermatitis occurred in half of the test sites. (40) Other studies have also shown that extended water exposure had effects which in themselves were not considered overtly damaging e.g. swelling of stratum corneum with increased epidermal thickness and dilation of intracellular spaces (41) (42) (43) (32) increased stratum corneum suppleness (44) (45) (46) enhanced mitotic rate, (47) and reduced cytokine IL-1 alpha mRNA levels. (48) (49)

It would therefore appear from the literature that reports on a range of clinical observations and investigations that hyper-hydration of the skin is biologically limited and does not necessarily result in sustained damage to the skin. Prolonged exposure of the skin to water results in a whitened or pearlescent appearance and is termed maceration.(50)

### **Maceration of the skin**

Maceration of peri-wound skin is defined as *“the softening and breaking down of skin resulting from prolonged exposure to moisture”*. (51) Maceration is a common aversion and although many clinical guidelines contain preventative recommendations (2) the origin of this apprehension would appear to be shrouded by history although some consider it may be related to the time when corrosive or irritating agents were used on wounds.(2)

The term Moisture Associated Skin Damage (MASD) is now accepted as the general term for inflammation or skin erosion caused by prolonged exposure to a source of moisture such as urine, stool, sweat, wound exudate, saliva, or mucus.(52) Moreover in order for MASD to occur, complicating factors are required in addition to moisture exposure, such as mechanical (friction), chemical (irritants contained in the moisture source), microbial or in the case of chronic wounds a significant complicating factor is the presence of wound exudate.(50, 53)

The synthesis of wound exudate is a normal part of wound healing, generally associated with the inflammatory stage.(54) It is an essential part of the wound healing process in that it provides a moist environment conducive to healing. Acute wound exudate is a milieu of biochemical (e.g. growth factors, cytokines, electrolytes, proteases and nutrients) cellular components (e.g. infiltrating white cells such as leucocytes) and proteins (e.g. fibrinogen and fibrin) that enable healing to

occur.(55) Chronic wounds, however, are typified by a state of non-resolving inflammation that is underpinned by disruption to the 'normal' biochemistry and cellular activity. (56) Chronic wound exudate contains an excess of protein degrading enzymes such as serine proteases such as plasmin and elastase and matrix metalloproteases (MMPs) e.g. MMP-2 and MMP-9, increased numbers of neutrophils together with an elevated profile of pro-inflammatory cytokines.(57) (56) In addition to endogenous proteases some bacterial species can produce powerful proteases and may contribute to the proteolytic damage of chronic wound exudate.(58) This results in a state that is non-concordant with homeostasis as proteases degrade growth factors and fibroblasts resulting in defective remodelling of the extracellular matrix (ECM).(59) Nearly two decades ago, chronic wound exudate was described as 'a wounding agent in its own right'. (60) Thus, excessive fluid is not *per se* the cause of skin damage but it is the content of the fluid that is of major importance. (27) The corrosive effect of chronic wound exudate leads to breakdown of the peri-wound skin, which in turn, can lead to wound enlargement, delayed healing, a higher risk of infection and increased pain and discomfort that results in a reduction in quality of life for the patient. (52, 61) Patient morbidity and cost of treatment will inevitably increase with the potential for hospitalisation and associated drawbacks. (62)

Maceration that occurs as a result of both over-hydration and the biochemical wound milieu is not only damaging but a significant management challenge. (63) (64) It is essential that clinical practitioners are able to identify the differences between peri-wound maceration and that of 'normal' hydration in order to achieve optimal outcomes. For example, newly formed (delicate) epithelial tissue can easily be mistaken for maceration as it often appears as pale white tissue. It is therefore important that the clinician takes into account the context in which suspected maceration occurs so that an accurate diagnosis is made.

Hyper-hydration of the skin (such as spending too long in the bath) can present as white wrinkly skin (Figure 1). A similar situation occurs when a wound dressing has not managed to maintain wound moisture balance e.g. when trans epidermal water loss (TEWL) is inhibited or when wound exudate remains in contact for extended periods of time with the peri-wound skin. Figure 2 shows over-hydrated skin on a finger due to inhibition of TEWL. In these two examples the 'maceration' is quickly and easily reversed. In contrast, Figure 3 demonstrates a chronic wound with a moderate to heavy level of exudate presenting as whitened skin with swelling and where the surface of the skin is not smooth, but is laced with multiple networks of fine grooves called sulci cutis.(65) (50) Figure 4 demonstrates grossly macerated peri-ulcer skin as a result of a combination of chronic wound exudate and prolonged dressing change intervals. Maceration may also be associated with

dermatitis/eczema (Figures 5 and 6) and may present with associated erythema, sloughy/necrotic tissue and extensive tissue breakdown of the wound/peri-wound skin.

### **Reversal of over-hydration of the skin**

It is important to note that some authors have inferred that skin damage caused by excessive hydration is reversible.(61) In support of this premise is data from a recent study<sup>62</sup> that investigated the hydration effects on skin microstructure and its implications in relation to enhancing transcutaneous delivery of bio-macromolecules. In this study cryo-scanning electron microscopy was used to investigate how hydration changes to the stratum corneum allowed penetration of macromolecules. The results showed that extended hydration (>8 h) caused swelling of the corneocytes, created inter-corneocyte rupture, and caused microstructural changes in lipid self-assembly. These disruptions allowed penetration (of bio-macromolecules) through the barrier of the stratum corneum, but importantly the disruptions were reversible, as removing the hydration source enabled restoration of the barrier.(66) This is further supported by data presented in another study in which the skin membrane electrical impedance properties under the influence of a varying water gradient was investigated. The results from this study concluded that hydration/dehydration induced reversible changes of membrane resistance and effective capacitance.(67)

### **Healing and hyper-hydration**

Although the term hyper-hydration is contemporary the underlying principle has a notable historical provenance. Junker (2013), records how Hebra, who published in 1861 his experience of patients with extensive burns and how they were treated by immersion in a bath using 'continuous baths' for months or years.(10) Bunyan claimed that the treatment, using water, reduced patients' pain, limited their weight loss and ensured their survival. When the continuous baths were stopped none of the patients survived. Later, during the Second World War John Bunyan, a medical officer in the Royal Navy treated wounded soldiers using the 'envelope' method. (68) Lieutenant Commander Bunyan used coated silk sheeting to envelope large burn wound area which acted as a trough into which a solution of electrolytically produced sodium hypochlorite would dwell for 20 minutes three times each day. Bunyan claimed that this method improved healing, cosmesis and avoided the use of painful dressing changes.(68)

More recently, Stenn and Yan investigated the effect of a liquid covering for superficial skin wounds and its effect on wound closure in a guinea pig wound model.(69) The results of this study showed that the animals tolerated the liquid bandage well and that no bacterial contamination or wound

maceration was evident. The extent of re-epithelialization with time was measured histologically under three separate conditions: wound exposed to air, wound covered and kept moist, and wound covered with liquid and the results showed that the liquid cover enhanced the rate of wound closure significantly.(69) In another experimental study that investigated the healing of partial thickness porcine skin wounds in a liquid environment the healing of fluid-treated wounds occurred without tissue maceration and showed less inflammation and less scar formation than healing of the air exposed wounds. (70)

Topical wound irrigation (intermittent or continuous) with either saline, water or isotonic solutions is a technique that provides the wound with a fluidic environment and has been used successfully as an aid to healing in many different wound types.(71, 72) A pilot study evaluating the effect of irrigation on two groups of patients with severely infected wounds treated with either a) continuous topical irrigation or b) with standard of care (no irrigation), n= 17 and 15 respectively has been reported. The results showed that irrigation improved severely infected wound healing through inhibition of pro-inflammatory cytokines and improving tissue regeneration when compared with the control group.(73) Fluidic therapy such as instillation combined with the use of adjunctive negative pressure wound therapy (NPWTi) has been shown to enhance exudate and debris removal, provide regular cleansing of the wound bed, and add moisture to the wound. Positive results have been demonstrated with this technique in assisting healing of static and painful wounds.(74)

These studies, uphold the view that innocuous fluid that remains in contact with the wound bed for extended periods of time supports healing and is tolerated well by patients.<sup>1</sup>

Wound dressings that provide part or complete occlusion and retain a degree of moisture content over the wound surface are *de rigueur* in the treatment of most acute and chronic wounds. Such dressings have been developed in many forms e.g. films,(75, 76) hydrocolloids,(77-79) foams(80, 81) and hydrofibres(82, 83) and new dressings and their components are still being developed with this aim in mind. (84)

The use of a dressing that provides a high fluid content was introduced over ten years ago and has since been further developed. The main characteristic of this wound dressing is that it maintains the wound in a fluidic environment of isotonic Ringers +solution. This dressing technology has been shown to be highly successfully in the treatment of acute (76) (85) and chronic wounds. (86) (87)

Maintaining a balanced moist environment for wounds is highly important. Advanced dressings are now able to cope with a full range of exudate levels from low to high. It is this ability to effectively

---



manage the balance between excessive moisture/exudate presence at the wound surface yet ensure a correct level of hydration that can otherwise complicate clinical practice.(88, 89) However an imbalance of moisture in conjunction with an acerbic wound fluid will cause tissue damage and maceration of the peri-wound skin.

Bolton (2) eloquently listed the dressing variables that require investigation to clarify clinical practice in relation to maceration:

- Wound dressings absorbency and adsorbency
- Wound dressing wicking characteristics
- Wound dressing capacity to retain fluid

These variables cannot be effectively examined in isolation of:

- The type and amount of exudate
- Pathology of peri-wound skin
- Potential sources of physical, chemical, metabolic, or vascular damage

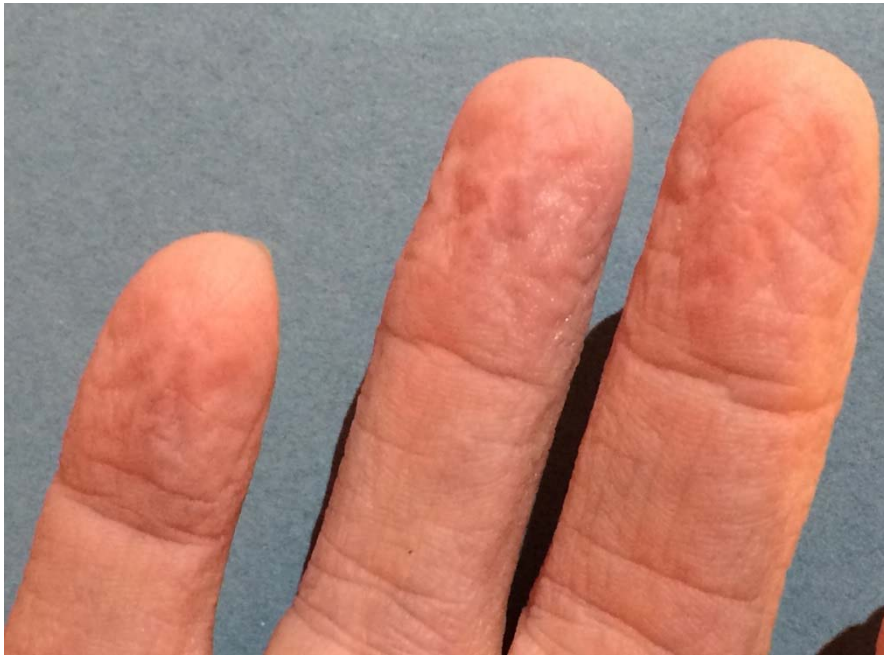**Conclusion:** Hydration is highly beneficial to wound healing but needs to be clearly differentiated from maceration (and the corrosive nature of chronic wound exudate). This is because, the negative physiological and clinical implications of maceration and its treatment/prevention is far removed from that of hydration. Unfortunately similarities in each presentation may cause confusion and unwarranted intervention that can lead to a wrong treatment pathway and ultimately be detrimental to the patient and the healing outcome of their wound. Healing through hyper-hydration is a counter-intuitive model that at first sight may appear incongruent with the more familiar moist healing paradigm. However, the isotonic nature of the fluid used in hyper-hydration together with the homeostatic mechanism of soft tissue, ensure that this approach to healing remains tenable.

## Tables and figures

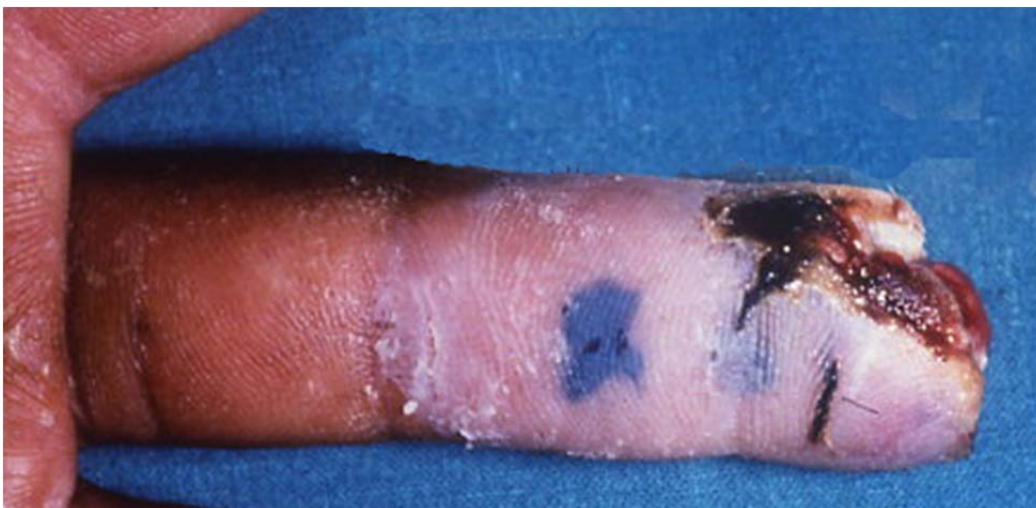**Table 1. Some advantages of moist wound treatment over dry wound treatment**

Effect	Experimental evidence	Clinical Evidence
Up to 50% faster wound healing. Faster wound contraction Enhanced and faster reepithelialisation  Generally increase cellular proliferation  Prolonged presence of growth factors and cytokines  Keratinocyte proliferation, fibroblast growth Promotes angiogenesis/revascularisation  Greater quantity and quality of ECM Collagen synthesis	Winter, 1962(5); Dyson, 1988(90)  Eaglstein 2001(17); Triller et al. 2012(91)  Svensjö et al., 2000(14); Hacki et al., 2014(15); Powers et al., 2013(92)  Svensjö et al., 2000(14); Rusak et al., 2013(93)  Dyson, 1992(94); Mosti et al., 2013(21)  Chen et al., 1992(95) ; Leung et al., 2007(96)	Falanga, 1988(97); Beam et al., 2008(98); Varghese et al., 1986(99); Rubio et al., 1991(100); Madden et al., 1989(101); Wigger-Alberti et al 2009(102)  Jones et al., 2007(103)  Romanelli et al 2004(104); Attinger et al., 2007(105); Harding, 2012(106)      Korting et al., 2011(77)  Field and Kerstein, 1994(107); Dowsett and Ayello, 2004(108):
Lower rate of infection.  Cleansing/irrigation		Hutchinson & Lawrence, 1991(109); Kannon & Garret, 1995(110); Rovee & Maibach, 2003(111); NICE, 2008(112)  Duleck et al., 2005(71); Hall, 2007(72); Tao et al., 2015(73)
Painless removal of the dressing without destroying newly formed tissue		Wiechula et al., 2003(113); Metzger, 2004: Leaper et al., 2012; Coutts et al., 2008
Less scarring and better cosmetic results.	Atiyeh et al ., 2003(18); O'Shaughnessy et al., 2009(114); Mustoe & Gurjala, 2012(22); Tandara et al., 2007(115)	Metzger, 2004(116); Atiyeh et al., 2004(117); Hoeksema et al., 2013(118)
Enhance autolytic debridement		Gray et al., 2005(119); King et al., 2014(23)
Decrease in initial donor site pain and improved donor site healing		Weber et al., 1995(24)

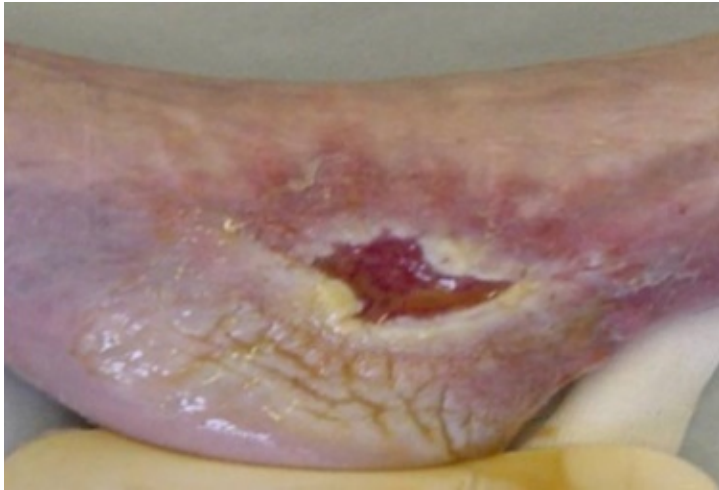
**Figures**



**Figure 1** Transient, hyper-hydration of the skin (wrinkling) following prolonged immersion in water. This is quickly reversed on exposure to air

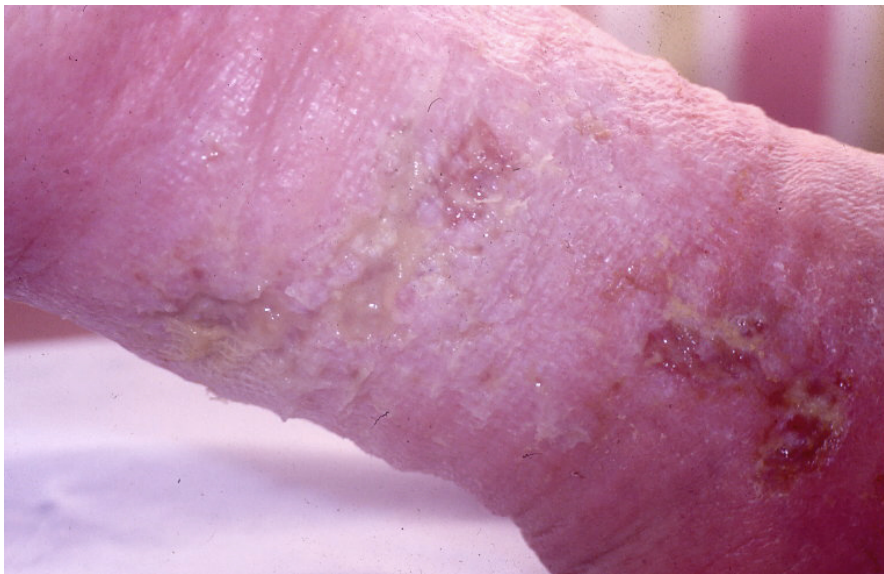

**Figure 2** Maceration of a finger as a result of inhibition of TEWL. This is promptly reversed on removal of occlusion.

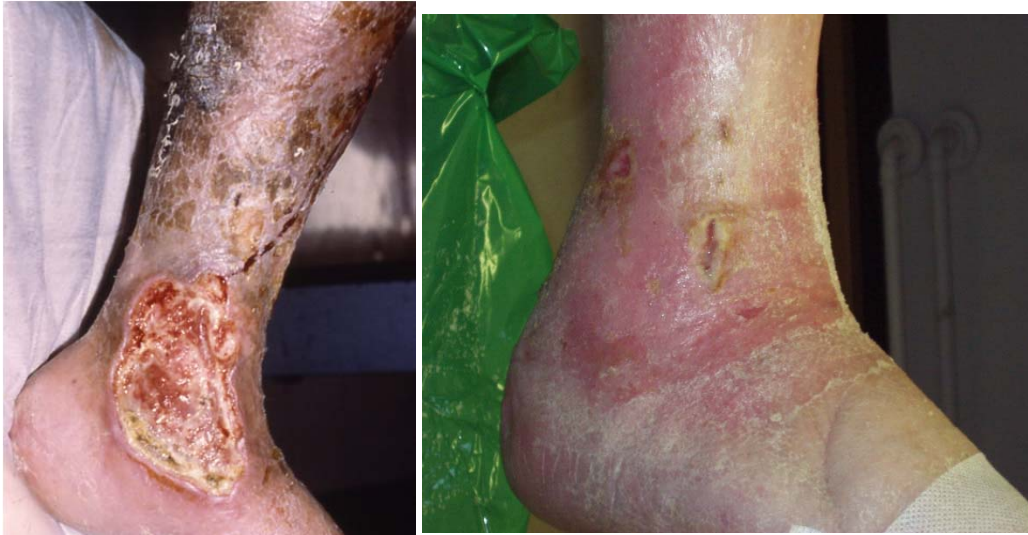

**Figure 3 Chronic wound with a moderate/heavy level of exudate**

**with whitened skin, swelling and where the surface of the skin is laced with multiple networks of fine grooves called sulci cutis**



**Figure 4 Grossly macerated peri-ulcer skin as a result of the combination of chronic wound exudate containing proteases and prolonged intervals between dressing change**



**Figures 5 & Figure 6 Maceration of venous leg ulcers with associated dermatitis/venous eczema**

## References

1. Cutting KF. The causes and prevention of maceration of the skin. *Journal of Wound Care*. 1999;8(4):200-1.
2. Bolton LL, Monte K, Pirone LA. Moisture and healing: beyond the jargon. *Ostomy Wound Manage*. 2000;46(1A Suppl):51S-62S; quiz 3S-4S.
3. Li J, Chen J, Kirsner R. Pathophysiology of acute wound healing. *Clinics in Dermatology*. 2007;25:9-18.
4. Johnson KE, Wilgus TA. Vascular Endothelial Growth Factor and Angiogenesis in the Regulation of Cutaneous Wound Repair. *Advances in Wound Care*. 2014;3(10):647-61.
5. Winter GD. Formation of the scab and rate of epithelialisation in the skin of the young domestic pig. *Nature*. 1962;193:293-5.
6. Winter GD. Effect of Air Exposure and Occlusion on Experimental Human Skin Wounds. *Nature*. 1963;200(4904):378-9.
7. Winter GD. A Note on Wound Healing Under Dressings with Special Reference to Perforated-film Dressings<sup>1</sup>. *The Journal of Investigative Dermatology*. 1965;45(4):299-302.
8. Winter GD, Scales JT. Effect of air drying and dressings on the surface of the wound. *Nature* is. 1963;97(4862):91-2.
9. Kruse CR, Nuutila K, Lee CC, Kiwanuka E, Singh M, Caterson EJ, et al. The external microenvironment of healing skin wounds. *Wound Repair Regen*. 2015;23(4):456-64.
10. Junker JP, Caterson EJ, Eriksson E. The microenvironment of wound healing. *The Journal of craniofacial surgery*. 2013;24(1):12-6.
11. Junker JPE, Kamel RA, Caterson EJ, Eriksson E. Clinical Impact Upon Wound Healing and Inflammation in Moist, Wet, and Dry Environments. *Advances in Wound Care*. 2013;2(7):348-56.
12. Evans ND, Oreffo RO, Healy E, Thurner PJ, Man YH. Epithelial mechanobiology, skin wound healing, and the stem cell niche. *Journal of the mechanical behavior of biomedical materials*. 2013;28:397-409.

13. Vogt PM, Andree C, Breuing K, Liu PY, Slama J, Helo G, et al. Dry, moist, and wet skin wound repair. *Ann Plast Surg.* 1995;34(5):493-9; discussion 9-500.
14. Svensjo T, Pomahac B, Yao F, Slama J, Eriksson E. Accelerated healing of full-thickness skin wounds in a wet environment. *Plast Reconstr Surg.* 2000;106(3):602-12; discussion 13-4.
15. Hackl F, Kiwanuka E, Philip J, Gerner P, Aflaki P, Diaz-Siso JR, et al. Moist dressing coverage supports proliferation and migration of transplanted skin micrografts in full-thickness porcine wounds. *Burns.* 2014;40(2):274-80.
16. Bryan J. Moist wound healing: a concept that changed our practice. *J Wound Care.* 2004;13(6):227-8.
17. Eaglstein WH. Moist wound healing with occlusive dressings: a clinical focus. *Dermatol Surg.* 2001;27(2):175-81.
18. Atiyeh BS, El-Musa KA, Dham R. Scar quality and physiologic barrier function restoration after moist and moist-exposed dressings of partial-thickness wounds. *Dermatol Surg.* 2003;29(1):14-20.
19. Erfurt-Berge C, Renner R. Recent Developments in Topical Wound Therapy: Impact of Antimicrobiological Changes and Rebalancing the Wound Milieu 2014. 8 p.
20. Atiyeh BS, Hayek SN. Intérêt d'un Onguent Chinois (MEBO) dans le Maintient Local de l'Humidité. *Journal des Plaies et Cicatrisation.* 2005;9:7-11.
21. Mosti G. Wound care in venous ulcers. *Phlebology.* 2013;28 Suppl 1:79-85.
22. Mustoe TA, Gurjala A. The role of the epidermis and the mechanism of action of occlusive dressings in scarring. *Wound Repair Regen.* 2011;19 Suppl 1:s16-21.
23. King A, Stellar JJ, Blevins A, Shah KN. Dressings and Products in Pediatric Wound Care. *Adv Wound Care (New Rochelle).* 2014;3(4):324-34.
24. Weber RS, Hankins P, Limitone E, Callender D, Frankenthaler RM, Wolf P, et al. Split-thickness skin graft donor site management. A randomized prospective trial comparing a hydrophilic polyurethane absorbent foam dressing with a petrolatum gauze dressing. *Archives of otolaryngology--head & neck surgery.* 1995;121(10):1145-9.
25. Ball P. *Life's Matrix: A Biography of Water*: University of California Press; 2001.
26. Popkin BM, D'Anci KE, Rosenberg IH. Water, hydration, and health. *Nutrition Reviews.* 2010;68(8):439-58.
27. Bishop SM, Walker M, Rogers AA, Chen WYJ. Importance of moisture balance at the wound dressing interface. *Journal of Wound Care.* 2003;12(4):125-8.
28. Proksch E, Brandner JM, Jensen JM. The skin: an indispensable barrier. *Exp Dermatol.* 2008;17(12):1063-72.
29. Pasparakis M, Haase I, Nestle FO. Mechanisms regulating skin immunity and inflammation. *Nature Reviews Immunology.* 2014;14:289-301.
30. Faria D, Fowler E, Carson SN. Understanding edema and managing the edematous lower leg. In: Krasner DL, Rodeheaver GT, Sibbald RG, editors. *Chronic Wound Care: a clinical source book for healthcare professionals - 3rd edition*. Malvern, PA, USA: HMP Publications; 2001. p. 525-40.
31. *The American Heritage® Medical Dictionary*. Boston: Houghton Mifflin; 2007.
32. Evans ME, Roth R. Shaping the Skin: The Interplay of Mesoscale Geometry and Corneocyte Swelling. *Physical Review Letters.* 2014;112(3):038102-1 - -5.
33. Changizi M, Weber R, Kotecha R, Palazzo J. Are wet-induced wrinkled fingers primate rain treads? *Brain, behavior and evolution.* 2011;77(4):286-90.
34. Kyriacos K, Nettle D, Smulders TV. Water-induced finger wrinkles improve handling of wet objects. *Biology Letters.* 2013;9(2):20120999.
35. Lewis T, Pickering GW. Circulatory changes in fingers in some diseases of the nervous system, with special reference to digital atrophy of peripheral nerve lesions. *Clinical Science.* 1936;2:149.

36. Hsieh C-H, Huang K-F, LiLiang P-C, Jeng S-F, Tsai H-H. Paradoxical response to water immersion in replanted fingers. *Clin Auton Res*. 2006;16(3):223-7.
37. Rietschel RL, Fowler JF. *Fisher's Contact Dermatitis*. 4th ed. Baltimore: Williams & Wilkins; 1995.
38. Willis I. The effects of prolonged water exposure on human skin. *J Investig Dermatol*. 1973;60(3):166-71.
39. Warner RR, Boissy YL, Lilly NA, Spears MJ, McKillop K, Marshall JL, et al. Water disrupts stratum corneum lipid lamellae: damage is similar to surfactants. *Journal of Investigative Dermatology*. 1999;113:960-6.
40. Rietschel RL, Allen AM. Effects of prolonged continuous exposure of human skin to water: a reassessment. *Journal of Investigative Dermatology*. 1977;68(2):79-81.
41. Scheuplein R, Ross L. Effects of Surfactants and Solvents on the Permeability of Epidermis. *Journal of the Society of Cosmetic Chemists*. 1970;21:853-73.
42. Egawa M, Hirao T, Takahashi M. In vivo estimation of stratum corneum thickness from water concentration profiles obtained with Raman spectroscopy. *Acta Derm Venereol*. 2007;87(1):4-8.
43. Scallan J, Huxley VH, Korthuis RJ. *Capillary Fluid Exchange: Regulation, Functions, and Pathology*. San Rafael, CA, USA: Morgan & Claypool Life Sciences; 2010.
44. Park AC, Baddiel CB. Rheology of stratum corneum. II. A physico-chemical investigation of factors influencing the water content of the corneum. *Journal of the Society of Cosmetic Chemists*. 1972;23:13-21.
45. Christensen MS, Hargens CW, 3rd, Nacht S, Gans EH. Viscoelastic properties of intact human skin: instrumentation, hydration effects, and the contribution of the stratum corneum. *J Invest Dermatol*. 1977;69(3):282-6.
46. Crowther JM, Sieg A, Blenkiron P, Marcott C, Matts PJ, Kaczvinsky JR, et al. Measuring the effects of topical moisturizers on changes in stratum corneum thickness, water gradients and hydration in vivo. *Br J Dermatol*. 2008;159(3):567-77.
47. Fisher LB, Maibach HI. Physical occlusion controlling epidermal mitosis. *J Invest Dermatol*. 1972;59(1):106-8.
48. Wood LC, Elias PM, Sequeira-Martin SM, Grunfeld C, Feingold KR. Occlusion lowers cytokine mRNA levels in essential fatty acid-deficient and normal mouse epidermis, but not after acute barrier disruption. *J Invest Dermatol*. 1994;103(6):834-8.
49. Gibbs S, Vietsch H, Meier U, Ponc M. Effect of skin barrier competence on SLS and water-induced IL-1 $\alpha$  expression. *Exp Dermatol*. 2002;11(3):217-23.
50. Ichikawa-Shigeta Y, Sugama J, Sanada H, Nakatani T, Konya C, Nakagami G, et al. Physiological and appearance characteristics of skin maceration in elderly women with incontinence. *J Wound Care*. 2014;23(1):18-9, 22-3, 6 passim.
51. Anderson KNE. *Mosby's Medical Nursing and Allied Health Dictionary*. St. Louis, MO: Mosby-Year Book; 1998.
52. Gray M, Weir D. Prevention and treatment of moisture-associated skin damage (maceration) in the periwound skin. *J Wound Ostomy Continence Nurs*. 2007;34(2):153-7.
53. Gray M, Black JM, Baharestani MM, Bliss DZ, Colwell JC, Goldberg M, et al. Moisture-associated skin damage: overview and pathophysiology. *J Wound Ostomy Continence Nurs*. 2011;38(3):233-41.
54. Kathryn Vowden PV. Understanding exudate management and the role of exudate in the healing process. *British Journal of Community Nursing*. 2003;8(11 (Exudate Suppl 2)):4-13.
55. Cutting KF. Wound exudate: composition and functions. *British Journal of Community Nursing*. 2003;8(9):(Suppl) 4-9.
56. Moore K. Cell biology of normal and impaired healing. In: S.L. Percival, K.F. Cutting, editors. *Microbiology of wounds*. Boca Raton, FL: CRC Press; 2010. p. 151-85.

57. Chen SM, Ward SI, Olutoye OO, Diegelmann RF, Kelman Cohen I. Ability of chronic wound fluids to degrade peptide growth factors is associated with increased levels of elastase activity and diminished levels of proteinase inhibitors. *Wound Repair Regen.* 1997;5(1):23-32.
58. Wildeboer D, Hill KE, Jeganathan F, Williams DW, Riddell AD, Price PE, et al. Specific protease activity indicates the degree of *Pseudomonas aeruginosa* infection in chronic infected wounds. *Eur J Clin Microbiol Infect Dis.* 2012.
59. Schultz GS, Sibbald RG, Falanga V, Ayello EA, Dowsett C, Harding K, et al. Wound bed preparation: a systematic approach to wound management. *Wound Repair Regen.* 2003;11 Suppl 1:S1-28.
60. Chen J. Aquacel hydrofibre dressing: The next step in wound dressing technology. Monograph. ConvaTec, London: 1998.
61. Thomas S. The role of dressings in the treatment of moisture-related skin damage <http://www.worldwidewounds.com/2008/march/Thomas/Maceration-and-the-role-of-dressings.html2008> [updated March 2008; cited 2012 1st April 2015].
62. Charlesworth B, Pilling C, Chadwick P, Butcher M. Dressing-related trauma: clinical sequelae and resource utilization in a UK setting. *ClinicoEconomics and outcomes research : CEOR.* 2014;6:227-39.
63. Ruttermann M, Maier-Hasselmann A, Nink-Grebe B, Burckhardt M. Local treatment of chronic wounds: in patients with peripheral vascular disease, chronic venous insufficiency, and diabetes. *Dtsch Arztebl Int.* 2013;110(3):25-31.
64. Martin P, Nunan R. Cellular and molecular mechanisms of repair in acute and chronic wound healing. *British Journal of Dermatology.* 2015;173(2):370-8.
65. Sussman C, Bates-Jensen BM. *Wound Care - a collaborative practice manual for health professionals - 4th edition.* Baltimore, MD, USA: Lippincott Williams & Wilkins; 2012.
66. Tan G, Xu P, Lawson LB, He J, Freytag LC, Clements JD, et al. Hydration effects on skin microstructure as probed by high-resolution cryo-scanning electron microscopy and mechanistic implications to enhanced transcutaneous delivery of biomacromolecules. *Journal of pharmaceutical sciences.* 2010;99(2):730-40.
67. Bjorklund S, Ruzgas T, Nowacka A, Dahi I, Topgaard D, Sparr E, et al. Skin membrane electrical impedance properties under the influence of a varying water gradient. *Biophysical journal.* 2013;104(12):2639-50.
68. Bunyan J. Treatment of Burns and Wounds by the Envelope Method. *British Medical Journal.* 1941;2(4200):1-7.
69. Stenn KS, Yan SP. Liquid covering for superficial skin wounds and its effect on wound closure in guinea pigs. *Biomaterials, medical devices, and artificial organs.* 1985;13(1-2):17-35.
70. Breuing K, Eriksson E, Liu P, Miller DR. Healing of partial thickness porcine skin wounds in a liquid environment. *J Surg Res.* 1992;52(1):50-8.
71. Dulecki M, Pieper B. Irrigating simple acute traumatic wounds: a review of the current literature. *Journal of emergency nursing: JEN : official publication of the Emergency Department Nurses Association.* 2005;31(2):156-60.
72. Hall S. A review of the effect of tap water versus normal saline on infection rates in acute traumatic wounds. *Journal of Wound Care.* 2007;16(1):38-41.
73. Tao Q, Ren J, Ji Z, Wang B, Zheng Y, Li J. Continuous topical irrigation for severely infected wound healing. *J Surg Res.* 2015;198(2):535-40.
74. Gabriel A, Kahn KM. New advances in instillation therapy in wounds at risk for compromised healing. *Surg Technol Int.* 2014;24:75-81.
75. Fletcher J. Using film dressings. *Nurs Times.* 2003;99(25):57.
76. Meuleneire F. A vapour-permeable film dressing used on superficial wounds. *British journal of nursing (Mark Allen Publishing).* 2014;23(15):S36, s8-43.



77. Korting HC, Schollmann C, White RJ. Management of minor acute cutaneous wounds: importance of wound healing in a moist environment. *Journal of the European Academy of Dermatology and Venereology* : JEADV. 2011;25(2):130-7.
78. Dumville JC, Deshpande S, O'Meara S, Speak K. Hydrocolloid dressings for healing diabetic foot ulcers. 2013 Contract No.: Art. No.: CD009099. DOI: 10.1002/14651858.CD009099.pub3.
79. Labud H, Bengough T, von Elm E. [Hydrocolloid in diabetic foot ulcers: better than current dressings?]. *Praxis*. 2014;103(15):907-8.
80. Brett DW. Impact on exudate management, maintenance of a moist wound environment, and prevention of infection. *J Wound Ostomy Continence Nurs*. 2006;33(6 Suppl):S9-14.
81. Yamane T, Nakagami G, Yoshino S, Muramatsu A, Matsui S, Oishi Y, et al. Hydrocellular foam dressing promotes wound healing along with increases in hyaluronan synthase 3 and PPARalpha gene expression in epidermis. *PLoS One*. 2013;8(8):e73988.
82. Brunner U, Eberlein T. Experiences with hydrofibres in the moist treatment of chronic wounds, in particular of diabetic foot. *VASA Zeitschrift fur Gefasskrankheiten Journal for vascular diseases*. 2000;29(4):253-7.
83. Vogt KC, Uhlyarik M, Schroeder TV. Moist wound healing compared with standard care of treatment of primary closed vascular surgical wounds: a prospective randomized controlled study. *Wound Repair Regen*. 2007;15(5):624-7.
84. Masood R, Miraftab M. Novel materials for moist wound management: alginate-psyllium hybrid fibres. *J Wound Care*. 2014;23(3):153-9.
85. Parker B. Rapid healing in a dehisced abdominal surgical wound using hydro-active dressings. Victoria, Australia: AWMA (VIC). Quarterly Publication, 2013 Contract No.: 4.
86. Konig M, Vanscheidt W, Augustin M, Kapp H. Enzymatic versus autolytic debridement of chronic leg ulcers: a prospective randomised trial. *J Wound Care*. 2005;14(7):320-3.
87. Humbert P, Faivre B, Véran Y, Debure C, Truchetet F, Bécherel PA, et al. Protease-modulating polyacrylate-based hydrogel stimulates wound bed preparation in venous leg ulcers – a randomized controlled trial. *Journal of the European Academy of Dermatology and Venereology*. 2014;28(12):1742-50.
88. Dini V, Barbanera S, Romanelli M. Quantitative Evaluation of Maceration in Venous Leg Ulcers by Transepidermal Water Loss (TEWL) Measurement. *International Journal of Lower Extremity Wounds*. 2014;13(2):116-9.
89. Sibbald RG, Elliott JA, Ayello EA, Somayaji R. Optimizing the Moisture Management Tighrope with Wound Bed Preparation 2015(c). *Adv Skin Wound Care*. 2015;28(10):466-76.
90. Dyson M, Young S, Pendle CL, Webster DF, Lang SM. Comparison of the effects of moist and dry conditions on dermal repair. *J Invest Dermatol*. 1988;91(5):434-9.
91. Triller C, Huljev D, Smrke DM. [Application of modern wound dressings in the treatment of chronic wounds]. *Acta medica Croatica : casopis Hravatske akademije medicinskih znanosti*. 2012;66 Suppl 1:65-70.
92. Powers JG, Morton LM, Phillips TJ. Dressings for chronic wounds. *Dermatol Ther*. 2013;26(3):197-206.
93. Rusak A, Rybak Z. [New directions of research related to chronic wound healing]. *Polimery w medycynie*. 2013;43(3):199-204.
94. Dyson M, Young SR, Hart J, Lynch JA, Lang S. Comparison of the effects of moist and dry conditions on the process of angiogenesis during dermal repair. *J Invest Dermatol*. 1992;99(6):729-33.
95. Chen WY, Rogers AA, Lydon MJ. Characterization of biologic properties of wound fluid collected during early stages of wound healing. *Journal of Investigative Dermatology*. 1992;99(5):559-64.

96. Leung BK, LaBarbera LA, Carroll CA, Allen D, McNulty AK. The effects of normal saline instillation in conjunction with negative pressure wound therapy on wound healing in a porcine model. *Wounds*. 2010;22(7):179-87.
97. Falanga V. Occlusive wound dressings: Why, when, which? *Archives of Dermatology*. 1988;124(6):872-7.
98. Beam JW. Occlusive Dressings and the Healing of Standardized Abrasions. *Journal of Athletic Training*. 2008;43(6):600-7.
99. Varghese MC, Balin AK, Carter D, Caldwell D. Local environment of chronic wounds under synthetic dressings. *Archives of Dermatology*. 1986;122(1):52-7.
100. Rubio PA. Use of semioclusive, transparent film dressings for surgical wound protection: experience in 3637 cases. *International surgery*. 1991;76(4):253-4.
101. Madden MR, Nolan E, Finkelstein JL, Yurt RW, Smeland J, Goodwin CW, et al. Comparison of an occlusive and a semi-occlusive dressing and the effect of the wound exudate upon keratinocyte proliferation. *J Trauma*. 1989;29(7):924-30; discussion 30-1.
102. Wigger-Alberti W, Kuhlmann M, Ekanayake S, Wilhelm D. Using a novel wound model to investigate the healing properties of products for superficial wounds. *J Wound Care*. 2009;18(3):123-28, 31.
103. Jones V, Harding K. Moist wound healing: optimizing the wound environment. In: Krasner DL, Rodeheaver GT, Sibbald RG, editors. *Chronic Wound Care: A Clinical Sourcebook for Healthcare Professionals 4th ed*. Malvern, PA, USA: HMP Communications; 2007. p. 199-204.
104. Romanelli M, Mastronicola D, Gaggio G. Noninvasive Physical Measurements of Wound Healing. In: Rovee DT, Maibach HI, editors. *The Epidermis in Wound Healing*. Boca Raton, USA: CRC Press; 2004. p. 135.
105. Attinger CE, Janis JE, Steinberg J, Schwartz J, Al-Attar A, Couch K. Clinical approach to wounds: debridement and wound bed preparation including the use of dressings and wound-healing adjuvants. *Plast Reconstr Surg*. 2006;117(7 Suppl):72s-109s.
106. Harding K. Assessing and Managing a Moist Wound Environment. *Consultant* 360. 2012;52(3).
107. Field FK, Kerstein MD. Overview of wound healing in a moist environment. *Am J Surg*. 1994;167(1a):2s-6s.
108. Dowsett C, Ayello E. TIME principles of chronic wound bed preparation and treatment. *British journal of nursing (Mark Allen Publishing)*. 2004;13(15):S16-23.
109. Hutchinson JJ, Lawrence JC. Wound infection under occlusive dressings. *J Hosp Infect*. 1991;17(2):83-94.
110. Kannon GA, Garrett AB. Moist wound healing with occlusive dressings. A clinical review. *Dermatol Surg*. 1995;21(7):583-90.
111. Thomas S. Wound dressings. In: Rovee DT, Maibach HI, editors. *The Epidermis in Wound Healing*. Boca Raton: CRC Press; 2003. p. 222.
112. NICE. *Surgical site infection prevention and treatment of surgical site infection*. London: RCOG Press, 2008.
113. Wiechula R. The use of moist wound-healing dressings in the management of split-thickness skin graft donor sites: a systematic review. *International journal of nursing practice*. 2003;9(2):S9-17.
114. O'Shaughnessy KD, De La Garza M, Roy NK, Mustoe TA. Homeostasis of the epidermal barrier layer: a theory of how occlusion reduces hypertrophic scarring. *Wound Repair Regen*. 2009;17(5):700-8.
115. Tandara AA, Kloeters O, Mogford JE, Mustoe TA. Hydrated keratinocytes reduce collagen synthesis by fibroblasts via paracrine mechanisms. *Wound Repair Regen*. 2007;15(4):497-504.
116. Metzger S. Clinical and Financial Advantages of Moist Wound Management. *Home Healthcare Nurse*. 2004;22(9):586-90.

117. Atiyeh BS, Dham R, Costagliola M, Al-Amm CA, Belhaouari L. Moist exposed therapy: an effective and valid alternative to occlusive dressings for postlaser resurfacing wound care. *Dermatol Surg.* 2004;30(1):18-25; discussion
118. Hoeksema H, De Vos M, Verbelen J, Pirayesh A, Monstrey S. Scar management by means of occlusion and hydration: a comparative study of silicones versus a hydrating gel-cream. *Burns.* 2013;39(7):1437-48.
119. Gray D, White R, Cooper P, Kingsley A. Using the wound healing continuum to identify treatment objectives. *Applied Wound Management supplement. Part 2. Wounds UK.* 2005;1(2):(Suppl) S9-S14.
120. Cutting KF, White RJ. Maceration of the skin and wound bed 1: its nature and causes. *Journal of Wound Care.* 2002;11(7):275-8.
121. Mugita Y, Minematsu T, Huang L, Nakagami G, Kishi C, Ichikawa Y, et al. Histopathology of Incontinence-Associated Skin Lesions: Inner Tissue Damage Due to Invasion of Proteolytic Enzymes and Bacteria in Macerated Rat Skin. *PLoS One.* 2015;10(9):e0138117.
122. Sarabahi S. Recent advances in topical wound care. *Indian journal of plastic surgery : official publication of the Association of Plastic Surgeons of India.* 2012;45(2):379-87.
123. Benbow M, Stevens J. Exudate, infection and patient quality of life. *British journal of nursing (Mark Allen Publishing).* 2010;19(20):S30, s2-6.
124. Colwell JC, Ratliff CR, Goldberg M, Baharestani MM, Bliss DZ, Gray M, et al. MASD part 3: peristomal moisture- associated dermatitis and periwound moisture-associated dermatitis: a consensus. *J Wound Ostomy Continence Nurs.* 2011;38(5):541-53; quiz 54-5.
125. Morgan D, Hoelscher J. Pulsed lavage: promoting comfort and healing in home care. *Ostomy Wound Manage.* 2000;46(4):44-9.
126. Butcher M. Introducing a new paradigm for bioburden management. *Journal of Wound Care.* 2011;20(Suppl 3):4-19.
127. Benbow M. Selecting a method for wound debridement. *Mims Dermatology.* 2008;4(2):50-1.
128. Kerstein MD. Moist wound healing: the clinical perspective. *Ostomy Wound Manage.* 1995;41(7A Suppl):37S-44S; discussion 5S.