



University of **HUDDERSFIELD**

University of Huddersfield Repository

Ousey, Karen and Cook, Leanne

Wound Assessment: Made Easy

Original Citation

Ousey, Karen and Cook, Leanne (2012) Wound Assessment: Made Easy. Wounds UK, 8 (2). ISSN 1746-6814

This version is available at <http://eprints.hud.ac.uk/id/eprint/16486/>

The University Repository is a digital collection of the research output of the University, available on Open Access. Copyright and Moral Rights for the items on this site are retained by the individual author and/or other copyright owners. Users may access full items free of charge; copies of full text items generally can be reproduced, displayed or performed and given to third parties in any format or medium for personal research or study, educational or not-for-profit purposes without prior permission or charge, provided:

- The authors, title and full bibliographic details is credited in any copy;
- A hyperlink and/or URL is included for the original metadata page; and
- The content is not changed in any way.

For more information, including our policy and submission procedure, please contact the Repository Team at: E.mailbox@hud.ac.uk.

<http://eprints.hud.ac.uk/>

Wound assessment

made easy

Introduction

A structured approach to wound assessment is required to maintain a good standard of care. This involves a thorough patient assessment, which should be carried out by skilled and competent practitioners, adhering to local and national guidelines (Harding et al, 2008). Inappropriate or inaccurate assessment can lead to delayed wound healing, pain, increased risk of infection, inappropriate use of wound dressings and a reduction in the quality of life for patients (Ousey and Cook, 2011). It is important that practitioners understand the elements of wound assessment: how to assess a wound; which wound assessment tools are available; and how to recognise a wound that may be failing to heal.

Authors: Ousey K, Cook L

WHAT IS WOUND ASSESSMENT?

A holistic assessment of the patient is essential to identify the causative or contributory factors and to highlight factors that could delay wound healing. It is about assessing the wound and wound bed, planning appropriate interventions, evaluating those interventions and continual reassessment. Accurate and timely wound assessment underpins effective clinical decision making, enabling appropriate goals to be set for the management of the wound in order to reduce morbidity and costs (Posnett et al, 2009).

The World Union of Wound Healing Societies (WUWHS) (2008) identified and discussed the importance of effective assessment and diagnosis in the treatment of wounds. They recommend that effective treatment of patients with wounds should encompass:

- Determination of the cause of the wound
- Identification of underlying medical conditions that may contribute to the wound or delay healing
- Assessment of the status of the wound
- Development of a management plan.

WHO SHOULD ASSESS THE WOUND?

Any practitioner who cares for a patient with a wound must possess the necessary skills to accurately assess and understand the results of those assessments, allowing development of an appropriate, evidence-based treatment plan. The initial assessment is generally undertaken by a nurse, member of the medical staff or a podiatrist. However,

involvement of the multidisciplinary team is integral to the wound assessment process. During assessment the practitioner should recognise the limits of their knowledge and refer the patient for specialist opinion when necessary (Eagle, 2009).

Involvement of the patient and their families/carers is crucial to ensure that the planned interventions are adhered to. This can be achieved by discussing the treatment options with the patient and offering clear explanations for the choice of treatment, which is based on the appropriate assessments.

WHAT DATA IS NEEDED TO COMPLETE A WOUND ASSESSMENT?

Wound assessment should include assessment of the patient and the wound to identify any factors that may delay healing. Results of all assessments must be clearly documented and include the recommended dates for reassessment.

Assessment of the patient

Taking a patient history and understanding their medical and surgical history is important to be able to assess and plan treatment for the wound. The wound should not be treated in isolation but in the context of the patient's overall wellbeing (Int Consensus, 2012). This should include an assessment of his/her psychological and nutritional status, pain and any medications the patient is receiving.

Assessment of the wound

Cause of the wound

Clear identification of the cause of the wound is important as this will guide the treatment plan. Clinicians should consider if the wound is acute or chronic and if it has been caused by pressure, infection, trauma, surgery, vascular insufficiency, neuropathy or an underlying condition. If the patient has more than one wound, each wound should be assessed individually and documented.

Wound size

Every wound should be measured and the results documented in the patient's notes at each dressing change. Visual documentation of the wound is useful and can be achieved through tracing or photographing the wound. If photographing the wound, ensure local guidance is adhered to and that the patient's permission is documented prior to the image being taken.

The linear depth of a wound can be calculated by an appropriately qualified practitioner who is familiar with the anatomy of the structures in close proximity to the wound. Taking a measurement of the wound can be done using a

sterile swab or curette, which is inserted into the maximum wound tract depth and documented (Maklebust, 1997).

Wound site

Documenting the site of the wound can help identify the underlying disease processes associated with its development. For example, uneven distribution of pressure on the foot can lead to diabetic foot ulcers, or unrelieved pressure on the sacrum can lead to a pressure ulcer.

Wound bed

The type of tissue within the wound bed will provide useful information relating to the expected healing time and risk of complications. Necrosis or eschar on a wound is usually black in appearance and is full thickness, dry, devitalised tissue due to prolonged local ischaemia (Gray et al, 2005). Tissue that presents as yellow is generally slough (Tong, 1999). This is creamy yellow in appearance and can be found dehydrated and adhered to the wound bed or loose and stringy when associated with increased wound moisture (Dowsett and Newton, 2005). Bright red granulation tissue, friable and exuberant tissue, new areas of slough, increased exudate, undermining and malodour are all signs of infection in a chronic wound (WUWHS, 2008). Red tissue is healthy, well vascularised tissue.

Signs and symptoms of infection

The wound should be assessed clinically for any signs or symptoms of infection. In an acute wound, these may include erythema, swelling, local warmth/heat and pain. These signs and symptoms may also be accompanied by purulent discharge and pyrexia. Identifying infection in chronic wounds is more challenging and clinicians may need to rely on a range of signs and symptoms for different wound types (EWMA, 2005). This should be done through repeated observation and appropriate treatment commenced promptly. The presence of infection will influence the treatment plan and choice of wound dressing.

Level of exudate

Observation for and recording of exudate levels of any wound is a part of the assessment process. The WUWHS (2007) suggest practitioners should assess and record four categories when assessing wound exudate: colour, consistency, odour and amount. Change in the volume or nature of exudate provides information on the state of wound healing and may give an indication of increasing bacterial load, which could influence wound healing (Cook and Barker, 2012).

Assessment of the surrounding skin

Assessment should identify whether the skin is erythematous, excoriated, indurated or macerated. A skin excoriation tool (Healthcare Improvement Scotland, 2009) provides a clear guide on identifying causes of surrounding skin damage.

Documentation

All observations, assessments, planned treatments, interventions and evaluations of wounds must be accurately documented in the patient's notes. The results of these must be clearly written avoiding jargon and using only abbreviations that have been sanctioned by the local healthcare area. A treatment plan can

be formed based on a complete assessment that can attempt to remove any factors that may delay healing. Any changes to the treatment plan must be documented and a rationale for any change recorded.

USING THE PRINCIPLES OF WOUND BED PREPARATION TO DEFINE THE TREATMENT PLAN

Wound bed preparation offers a structured and systematic approach to assist clinicians when assessing and managing patients with wounds. The International Advisory Board on Wound Bed Preparation developed the acronym TIME (T = Tissue, non-viable or deficient; I = Infection or inflammation; M = Moisture imbalance; E = Edge of wound, non-advancing or undermined). Assessment is an essential part of wound bed preparation and can be used to decide on the most appropriate treatment options to optimise wound healing (Falanga, 2004) (Table 1).

Tissue

Accurate assessment of the wound bed to differentiate between viable and non-viable/devitalised tissue will ensure appropriate treatment planning:

- **Viable tissue** — includes granulation and epithelial tissue
- **Non-viable tissue** — includes black necrotic tissue (also known as eschar) and slough (Table 2).

Non-viable tissue will impair wound healing and should be removed using an appropriate debridement method to restore the wound bed.

Infection and inflammation

If the wound is infected, prompt treatment is required to prevent complications such as sepsis and to reduce discomfort and pain. All wounds contain bacteria, ranging

Table 2 Recognising different tissue types

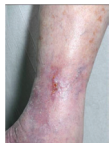





Viable tissue	Granulating tissue	
	Epithelial tissue	
Non-viable tissue	Necrotic tissue	
	Sloughy tissue	

Table 1 Using the principles of wound bed preparation to define the treatment plan

Wound					
Clinical presentation	Mixed disease leg ulcer with surrounding cellulitis, which would cause increased pain, increased exudate, and the patient feeling generally unwell	Highly exuding venous leg ulceration with surrounding skin damage	Mixed disease leg ulcer which is failing to heal due to inadequate vascular supply in combination with oedema. The wound is covered with sloughy tissue	Venous leg ulcer being treated with non-adherent dressings and a compression hosiery kit. Wound bed shows 100% healthy granulation tissue with evidence of advancing epithelial edges	Dehiscent abdominal wound which has been treated with negative pressure wound therapy (NPWT). The wound bed shows 100% healthy granulation tissue
Treatment plan	Accurate assessment of the arterial supply is required to establish whether treatment should be revascularisation or reduced compression. Cellulitis will require treatment with antibiotics	Requires adequate moisture control in combination with compression therapy to address the underlying cause	Accurate assessment of arterial supply to establish whether treatment should be revascularisation or reduced compression. Wound requires debridement to remove sloughy tissue to promote healing	Continue treatment with non-adherent dressings and compression hosiery	Discontinue NPWT as the wound bed is now at the surface level. An appropriate dressing should be selected to maintain a moist environment to promote epithelialisation

from contamination, to critical colonisation and infection. It is only when bacterial levels reach a 'critical colonised' state or when the wound becomes clinically infected that treatment with either antimicrobial dressings or systemic antibiotics is indicated. A microbial swab may assist when deciding on the most appropriate antibiotic, but should not be used routinely to diagnose wound infection (WUWHS, 2008).

Moisture

A moist wound environment is needed to enhance the autolytic process and acts as a transport medium for essential growth factors during epithelialisation (Cutting and Tong, 2003). If the wound becomes too dry this will slow epithelial migration, but if the wound is too wet, the exudate may damage the periwound skin and cause maceration. The choice of wound dressing to manage high levels of exudate is important for wound healing (Cook and Barker, 2012). In addition, dressings should aim to minimise maceration and leakage as well as reducing odour.

Edges

Failure of a wound to heal can be diagnosed through a lack of improvement in wound dimensions and the epidermal edge failing to improve (Ousey and Cook, 2011). The European Wound Management Association (EWMA) (2008) suggested that a useful general measure of healing outcomes in different wound types is through recognition of a reduction in wound size by measuring the advancement of the wound edge (epithelial advancement).

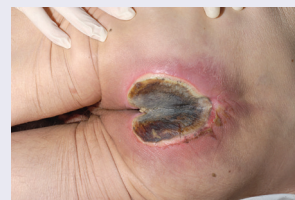THE ROLE OF DEBRIDEMENT

Non-viable tissue requires debridement to prevent delays in wound healing: debridement can be episodic or continuous over a period of a few weeks. Many options are available to debride wounds, including autolytic, sharp, biological, enzymatic or mechanical (Vowden and Vowden, 2010). The

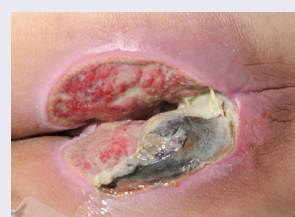method of debridement will vary according to a variety of factors such as the amount and type of non-viable tissue, patient choice, the availability of equipment, the environment, pain, practitioner skills, and time and speed that is required to remove the devitalised tissue (Gray, 2011).

Devitalised tissue provides an excellent medium for the growth of anaerobic and aerobic bacteria (O'Brien, 2002), which can lead to delayed wound healing and significant malodour. Debridement can help to control the bacterial burden within the wound (Falabella, 2006), while the removal of sloughy devitalised tissue can assist in controlling excessive exudate levels (Falabella, 2006), which is important to prevent surrounding tissue damage.

Box 1 Using debridement to accurately assess a sacral pressure ulcer



Sacral pressure ulcer which is failing to heal due to the amount of devitalised tissue within the wound. This requires debridement to assess the true extent of tissue damage and allow healing to occur



Following debridement of the covering eschar the extent of tissue involvement can be truly assessed and in this case debridement revealed tissue and muscle damage with a cavity that could be probed to bone

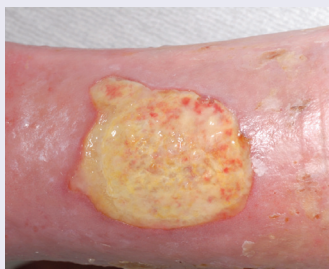

Figure 1: Superficial sloughy wound, which is suitable for active debridement using a simple debridement pad (ie Debrisoft)

True assessment of the depth of a wound can be difficult, if not impossible, when the wound is covered with devitalised tissue. Debridement is required to accurately assess the depth of tissue damage and to establish whether there is involvement of superficial tissue, muscle, tendon or bone (see Box 1).

Debrisoft® (Activa Healthcare) is a non-traumatic method of mechanical debridement that can be used to remove debris and devitalised sloughy tissue from the wound bed fast and effectively without causing trauma to the patient (Bahr, 2011). Debrisoft comprises a pad made from monofilament polyester fibres, which is wetted like a cloth and gently wiped over the wound bed. It does not require any specialist training and can be used by generalist nurses (Figure 1). By removing the non-viable tissue, slough and excess exudate it is possible to visualise the wound bed more accurately. This can help with diagnosis and treatment planning (Stephen-Haynes and Callaghan, 2012).

BENEFITS OF ACCURATE WOUND ASSESSMENT

Accurate holistic assessment of the patient and the wound will provide an understanding of primary treatment objectives resulting in improved patient outcomes and reduced costs. Practitioners involved in wound care need to ensure they have the essential skills required to plan, implement and evaluate care on an individual basis (Cook, 2011).

Suboptimal care can lead to delayed healing, increased pain, increased infection and inappropriate use of wound dressings, all of which impact on patients' quality of life. Clinicians working in the NHS are under pressure to reduce costs while increasing the quality of care. It is vital therefore that holistic wound assessment is seen as an essential aspect of care for every individual living with a wound.

AUTHOR DETAILS

Ousey K¹, Cook L²

1. Reader in Advancing Clinical Practice, School of Human and Health Sciences, The University of Huddersfield
2. Lecturer Practitioner, Division of Podiatry, Department of Health Sciences, The University of Huddersfield

REFERENCES

- Bahr S, Mustafi N, Hattig P et al (2011) Clinical efficacy of a new monofilament fibre containing wound debridement product. *J Wound Care* 20(5): 242-8
- Cook L (2011) Wound assessment: exploring competency and current practice. *Br J Comm Nurs* 16(12): S34-S40
- Cook L, Barker C (2012) Exudate: Understand it, assess it, manage it. *Nurs Res Care* 14(5): 234-38
- Cutting KF, Harding KG (1994) Criteria for identifying wound infection. *J Wound Care* 3: 198-201
- Cutting K, Tong A (2003) *Wound physiology and moist wound healing*. Medical Communications Ltd, Holsworthy
- Dowsett C, Newton H (2005) Wound bed preparation: TIME in practice. *Wounds UK* 1(3): 58-70
- Eagle M (2009) Wound assessment: The patient and the wound. *Wound Essentials* 4: 14-24
- EWMA (2005) *Position Document. Identifying criteria for wound infection*. London: MEP Ltd. Available from: www.woundsinternational.com
- EWMA (2008) *Position Document. Hard-to-Heal Wounds: A Holistic Approach*. London: MEP Ltd. Available from: www.woundsinternational.com
- Falabella AF (2006) Debridement and wound bed preparation. *Dermatol Ther* 19(6): 317-25.
- Falanga V (2004) Wound bed preparation: science applied to practice. In: *EWMA. Position Document: Wound Bed Preparation in Practice*. London: MEP Ltd. Available from: www.woundsinternational.com
- Gray D, White R, Cooper P, Kingsley A (2005) Using the wound healing continuum to identify treatment objectives. *Applied Wound Management*. Part 2. *Wounds UK* 1(2): S9-S14
- Gray D, Acton C, Chadwick P, et al (2011) Consensus guidance for the use of debridement techniques in the UK. *Wounds UK* 7(1): 77-84
- Harding KG et al (2008) Best Practice Statement Optimising Wound Care. *Wounds UK*. Available from: www.wounds-uk.com
- Health Improvement Scotland (2009) Excoriation tool. Available from: <http://tiny.cc/xnx0ew>
- International Consensus. *Optimising wellbeing in people living with a wound*. Wounds International 2012. Available from: www.woundsinternational.com
- Maklebust J (1997) Pressure ulcer assessment. *Clin Geriatr Med* 13; 144-81
- O'Brien M (2002) Exploring methods of wound debridement. *Br J Community Nur* 7(12): 10-18.
- Ousey K, Cook L (2011) Understanding the importance of holistic wound assessment. *Pract Nurse* 22 (6): 308-14
- Posnett J, Gotttrup F, Lundgren H, Saal G (2009) The resource impact of wounds on health care providers in Europe. *J Wound Care* 18(4): 154-61
- Stephen-Haynes J, Callaghan R (2012) The role of an active debridement system in assisting the experienced clinician to undertake an assessment and determine appropriate wound management objectives. Poster presentation, EWMA, Vienna
- Tong A (1999) The identification and treatment of slough. *J Wound Care* 8(7): 338-9
- Vowden K, Vowden P (2011) Debridement made easy. *Wounds UK* 7(4). Available from www.wounds-uk.com
- WUWHS (2007) *Wound exudate and the role of dressings. A consensus document*. London: MEP Ltd. Available from www.woundsinternational.com
- WUWHS (2008) *Wound infection in clinical practice. A consensus document*. London: MEP Ltd, 2008.

Supported by Activa Healthcare

To cite this document: Ousey K, Cook L (2012) Wound assessment made easy. *Wounds UK* 8(2). Available from www.wounds-uk.com/made-easy