



University of HUDDERSFIELD

University of Huddersfield Repository

Oji, V., Preil, M.L., Kleinow, B., Wehr, G., Fischer, J., Hennies, Hans C., Hausser, I., Breitzkreutz, D., Aufenvenne, K., Stieler, K., Tantcheva- Poór, I., Weidinger, S., Emmert, S., Hamm, H., Perusquia-Ortiz, A.M., Zaraeva, I., Diem, A., Giehl, K., Fölster-Holst, R., Kiekbusch, K., Höger, P., Ott, H. and Traupe, H.

S1 guidelines for the diagnosis and treatment of ichthyoses – update

Original Citation

Oji, V., Preil, M.L., Kleinow, B., Wehr, G., Fischer, J., Hennies, Hans C., Hausser, I., Breitzkreutz, D., Aufenvenne, K., Stieler, K., Tantcheva- Poór, I., Weidinger, S., Emmert, S., Hamm, H., Perusquia-Ortiz, A.M., Zaraeva, I., Diem, A., Giehl, K., Fölster-Holst, R., Kiekbusch, K., Höger, P., Ott, H. and Traupe, H. (2017) S1 guidelines for the diagnosis and treatment of ichthyoses – update. *Journal der Deutschen Dermatologischen Gesellschaft*, 15 (10). pp. 1053-1065. ISSN 1610-0379

This version is available at <http://eprints.hud.ac.uk/id/eprint/33816/>

The University Repository is a digital collection of the research output of the University, available on Open Access. Copyright and Moral Rights for the items on this site are retained by the individual author and/or other copyright owners. Users may access full items free of charge; copies of full text items generally can be reproduced, displayed or performed and given to third parties in any format or medium for personal research or study, educational or not-for-profit purposes without prior permission or charge, provided:

- The authors, title and full bibliographic details is credited in any copy;
- A hyperlink and/or URL is included for the original metadata page; and
- The content is not changed in any way.

For more information, including our policy and submission procedure, please contact the Repository Team at: E.mailbox@hud.ac.uk.

<http://eprints.hud.ac.uk/>



S1 guidelines for the diagnosis and treatment of ichthyoses – update

Vinzenz Oji¹, Marie-Luise Preil², Barbara Kleinow³, Geske Wehr⁴, Judith Fischer⁵, Hans Christian Hennies⁶, Ingrid Hausser⁷, Dirk Breitzkreutz⁸, Karin Aufenvenne⁹, Karola Stieler¹⁰, Illiana Tantcheva-Poór¹¹, Stefan Weidinger¹², Steffen Emmert¹³, Henning Hamm¹⁴, Ana Maria Perusquia-Ortiz¹⁵, Irina Zaraeva¹, Anja Diem¹⁶, Kathrin Giehl¹⁷, Regina Fölster-Holst¹², Kirstin Kiekbusch¹⁸, Peter Höger¹⁹, Hagen Ott²⁰, Heiko Traupe¹

- (1) Department of Dermatology – General Dermatology and Venereology, Münster University Medical Center, Von-Esmarch-Str. 58, 48149, Münster, Germany
- (2) Dermatology Practice am Färberturm, Weißenburger Str. 19, 91710, Gunzenhausen, Germany
- (3) Raiffeisenstr. 15, 57482, Wenden OT Dörnscheid, Germany
- (4) In den Dellen 21, 51515, Kürten-Hufe, Germany
- (5) Institute for Human Genetics, Freiburg University Hospital, Breisacher Str. 33, D-79106, Freiburg i. Br., Germany
- (6) Department of Dermatogenetics, University of Cologne, Weyertal 115b, 50931, Cologne, Germany
- (7) Pathology IPH, EM Laboratory, Heidelberg University Hospital, INF 224, 69120, Heidelberg, Germany
- (8) German Society for Cell Biology/German Cancer Research Center Heidelberg & Mannheim University of Applied Sciences, Im Fuchsloch 18, 69221, Dossenheim/bei Heidelberg, Germany
- (9) IUF – Leibniz Research Institute for Environmental Medicine, Auf'm Hennekamp 50, 40225, Düsseldorf, Germany
- (10) Charité Berlin – University Medicine, Mitte Campus, Outpatient Clinic for Pediatric Dermatology at Mitte Campus, Department of Dermatology, Venereology, and Allergology, Schumannstr. 20–21, 10117, Berlin, Germany
- (11) Department of Dermatology, Cologne University Hospital, Kerpener Str. 62, 50937, Cologne, Germany
- (12) Department of Dermatology, Venereology and Allergology, University Hospital Schleswig-Holstein, Kiel Campus, Schittenhelmstr. 7, 24105, Kiel, Germany
- (13) Department of Dermatology and Venereology, University Medicine Rostock, Strepelstr. 13, 18057, Rostock, Germany
- (14) Department of Dermatology, Venereology, and Allergology, Würzburg University Hospital, Josef-Schneider-Str. 2, 97080, Würzburg, Germany
- (15) Dermatology Practice Tentrup/Köster-Tentrup, Weberstr. 40, 49477, Ibbenbüren, Germany

1
2
3
4
5
6
7
8
9
10
11
12
13
14
15
16
Q1 17
18
19
20
21
22
23
24
25
26
27
28
29
30
31
32
33
34
35
36
37
38
39
40
41
42
43
44
45
46
47
48
49
50
51
52

1
2
3
4
5
6
7
8
9
10
11
12
13
14
15
16
17
18
19
20
21
22
23
24
25
26
27
28
29
30
31
32
33
34
35
36
37
38
39
40
41
42
43
44
45
46
47
48
49
50
51
52

(16) EB House Austria, Department of Dermatology, Salzburg Medical Center, Paracelsus Private Medical University, Müllner Hauptstr. 48, A-5020, Salzburg, Austria
 (17) Center for Rare and Genetic Skin Diseases, Department of Dermatology and Allergology, LMU Munich, Frauenlobstr. 9–11, 80337, Munich, Germany
 (18) Kirstin Kiebusch, Straße der Einheit 5d, 15749, Mittenwalde/Brusendorf, Germany
 (19) Center for Pediatric and Adolescent Medicine, Liliencronstr. 130, 22149, Hamburg, Germany
 (20) Department of Pediatric Dermatology and Allergology, Center for Pediatric and Adolescent Medicine, Children’s Hospital Auf der Bult, Janusz-Korczak-Allee 12, 30173, Hanover, Germany.

Summary

Ichthyoses are a group of rare genetic skin disorders that pose numerous clinical challenges, in particular with respect to the correct diagnosis and appropriate management. The present update of the German ichthyosis guidelines addresses recent diagnostic advances that have resulted in the Sorèze consensus classification. In this context, we provide an updated diagnostic algorithm, taking into account clinical features as well as the molecular genetic basis of these disorders. Moreover, we highlight current therapeutic approaches such as psychosocial support, balneotherapy, mechanical keratolysis, topical therapy, and systemic retinoid therapy. General aspects such as the indication for physical therapy, ergotherapy, or genetic counseling are also discussed. The present update was consented by an interdisciplinary consensus conference that included dermatologists, pediatricians, human geneticists, and natural scientists as well as representatives of the German patient support organization Selbsthilfe Ichthyose e. V.

1 Definition, classification, and objective

Ichthyoses comprise a heterogeneous group of genetic diseases characterized by abnormal keratinization that involves the entire skin [1, 2]. Primary clinical symptoms include thickening of the stratum corneum, xerosis, and visible scaling. Furthermore, the ability to perspire is frequently markedly decreased, which can lead to hyperthermia and eventually circulatory collapse [2]. Two main groups can be distinguished [2]:

- ▶ (Nonsyndromic) ichthyoses only affecting the skin (ichthyosis vulgaris, autosomal recessive congenital ichthyosis, epidermolytic ichthyosis, and others)
- ▶ Ichthyosis syndromes that are characterized by the involvement of other organ systems in addition to the skin (Chanarin-Dorfman syndrome, Comèl-Netherton syndrome, KID syndrome, Refsum’s disease, Sjögren-Larsson syndrome [SLS], trichothiodystrophy, and others)

Differentiating common forms of ichthyosis (ichthyosis vulgaris, X-linked recessive ichthyosis) from rare ichthyosis variants, which are frequently already present at

birth, is the key to adequate diagnostic management. Clinical manifestations of these congenital ichthyoses include collodion baby or congenital ichthyosiform erythroderma (CIE). Today, the various forms of erythrokeratoderma are classified as ichthyoses [2]. There is some overlap with palmoplantar keratoses, for example in the case of loricrin keratoderma.

Given that hereditary ichthyoses are genetic disorders, no cure is possible to date. There are, however, options to mitigate their symptoms. The diagnostic workup has a positive impact with respect to how individuals cope with the disease; it is perceived as concrete support by patients and their families. The present guidelines pursue the following objectives:

- ▶ Diagnostic clues in the workup of ichthyoses
- ▶ Summary of the options available for symptomatic treatment taking into account current literature and expert consensus
- ▶ Information on clinical/diagnostic centers in Germany
- ▶ Given the rarity and complexity of ichthyosis disorders and syndromes, the guidelines focus on the fundamentals of the general diagnostic workup and treatment of ichthyoses. Peculiarities of important individual ichthyosis variants are highlighted.

1.1 Nonsyndromic ichthyoses

Table 1 lists important nonsyndromic ichthyoses, their mode of inheritance, and the genes associated with the disorder (to the extent known to date).

1.2 Syndromic ichthyoses

A list of ichthyosis syndromes can be found in Table 2. The skin changes associated with syndromic ichthyoses are not always of primary importance. Here, the other prominent clinical features listed are meant to serve as diagnostic clues.

1.3 Diagnostic criteria for differentiation

Apart from clinical criteria, ichthyoses can be classified using the following diagnostic methods [2–4]:

- ▶ Histology and immunohistochemistry [5],
- ▶ Ultrastructural/electron microscopy [6, 7],
- ▶ Molecular genetic studies [2, 4, 8].

2 Etiology

Common to all ichthyoses is the occurrence of genetically determined epidermal changes, resulting in decreased water-binding capacity and impairment of the skin’s barrier function [9].

Most forms histologically classified as non-epidermolytic are characterized by impaired terminal epidermal differentiation, which primarily affects the granular and corneal layers. The primary pathogenetic change associated with classic epidermolytic ichthyoses is located in the stratum spinosum (abnormal cytoskeleton caused by mutations in keratins 1, 2 or 10, which are expressed depending on differentiation), and explains their tendency for skin fragility, especially among newborns. Some ichthyoses marked by pronounced inflammation are associated with defects in cell adhesion proteins (connexinopathies, corneodesmosin deficiency, and others) or of the epidermal protease equilibrium (for example, LEKTI deficiency in case of Netherton syndrome). For some entities, the exact pathomechanism of the skin changes has to date not been elucidated (DNA repair gene defects) [10, 11].

3 Epidemiology

The most common forms of ichthyosis are ichthyosis vulgaris (prevalence of 1 in 100–1 in 1,000) [8], X-linked recessive ichthyosis (prevalence of 1 in 4,000) [8], autosomal recessive congenital ichthyosis (prevalence of 1 in 60,000–1 in 200,000) [12] and epidermolytic ichthyoses (prevalence of 1 in 200,000–1 in

500,000) [3]. While this makes X-linked recessive ichthyosis a rare disease according to EU classification (prevalence lower than 1 in 2,000), it is still considered to be part of the “common” disease variants within the spectrum of ichthyoses. All other forms must ultimately be considered to be exceedingly rare.

4 Diagnosis

4.1 History and clinical findings

A standardized history and clinical findings form is provided by the Network for Ichthyoses and Related Keratinization Disorders (NIRK)/Münster Center for Rare Diseases (<http://www.netzwerk-ichthyose.de/index.php?id=23>). It includes the following questions:

- ▶ Initial manifestation of ichthyosis: manifestation at birth, course and length of pregnancy, polyhydramnion, birth complications, clinical findings at birth, collodion membrane, blistering, exfoliation, ectropion, eclabium, erythroderma, ear deformities, joint contractures, infections, other extracutaneous symptoms (see below)
- ▶ Family history, pedigree, question about consanguinity
- ▶ Clinical course after birth, during childhood/adulthood, seasonal variability
- ▶ Current clinical findings: light/dark brown/black, fine, coarse lamellar/plate-like scaling; mild/moderate/severe erythema; pattern of involvement (generalized/localized); involvement of the antecubital/popliteal fossae; palmoplantar hyperlinearity and/or keratosis; blistering; exfoliation; keratotic lichenification; signs of impaired ability to perspire/impaired thermoregulation with tendency for hyperthermia; photosensitivity
- ▶ Skin appendages: alopecia, hypotrichosis, hair shaft anomalies, nail anomalies
- ▶ Extracutaneous symptoms: visual/ocular/hearing impairment; joint contractures; skeletal anomalies; tooth anomalies; visceral, neurological, motor impairment; mental retardation; hepatomegaly (transaminases); cryptorchidism, vitamin D deficiency, metabolic disorders (Jordan’s anomaly), type I hypersensitivities (CBC with differential, IgE)

4.2 Clinical (differential) diagnostic clues

Establishing the correct clinical diagnosis requires answers to the following questions:

1. Has the ichthyosis been present since birth? Differentiation between rare congenital forms of ichthyosis, which are present at birth or shortly thereafter, and common ichthyosis forms that tend to manifest themselves at a later point in time (ichthyosis vulgaris).

Table 1 Nonsyndromic ichthyoses.

Disorder	Mode of inheritance	Gene(s)
Common ichthyoses		
Ichthyosis vulgaris (IV) [146700]	Autosomal semi-dominant	<i>FLG</i>
X-linked recessive ichthyosis (XRI)		
Nonsyndromic presentation [308100]	XR	<i>STS</i>
Autosomal recessive congenital ichthyosis (ARCI)		
Harlequin ichthyosis		
ARCI4B [242500]	AR	<i>ABCA12</i>
Lamellar ichthyosis (LI) / congenital ichthyosiform erythroderma (CIE)		
ARCI1 [242300]		<i>TGM1</i>
ARCI2 [242100]		<i>ALOX12B</i>
ARCI3 [606545]		<i>ALOXE3</i>
ARCI4A [601277]		<i>ABCA12</i>
ARCI5 [604777]		<i>CYP4F22</i>
ARCI6 [612281]		<i>NIPAL4</i>
ARCI8 [613943]	AR	<i>LIPN</i>
ARCI9 [615023]		<i>CERS3</i>
ARCI10 [615024]		<i>PNPLA1</i>
ARCI11 [602400]		<i>ST14</i>
ARCI12 [617320]		<i>CASP14</i>
Self-improving congenital ichthyosis (SICI)		
ARCI1 [242300]		<i>TGM1</i>
ARCI2 [242100]	AR	<i>ALOX12B</i>
ARCI3 [606545]		<i>ALOXE3</i>
Bathing suit ichthyosis (BSI)		
ARCI1 [242300]	AR	<i>TGM1</i>
Keratinopathic ichthyosis (KPI)		
Epidermolytic ichthyosis (EI) [113800]	AD	<i>KRT1 / KRT10</i>
Superficial epidermolytic ichthyosis (SEI) [146800]	AD	<i>KRT2</i>
KPI variants		
Annular epidermolytic ichthyosis (AEI) [607602]	AD	<i>KRT1 / KRT10</i>
Ichthyosis Curth-Macklin (ICM) [146590]	AD	<i>KRT1</i>
Autosomal recessive epidermolytic ichthyosis (AREI) [113800]	AR	<i>KRT10</i>
Congenital reticular ichthyosiform erythroderma (CRIE) [609165]	AD	<i>KRT10 / KRT1</i>
Epidermolytic nevi [113800]	Postzygotic mosaicism	<i>KRT1 / KRT10</i>
Other nonsyndromic ichthyoses		
Loricrin keratoderma (LK) [604117]	AD	<i>LOR</i>
Erythrokeratoderma variabilis (EKV) [133200]	AD	<i>GJB3/GJB4</i>
Peeling skin disease (PSD) [270300]	AR	<i>CDSN</i>
Keratosis linearis with ichthyosis congenita and sclerosing keratoderma (KLICK) [601952]	AR	<i>POMP</i>

Q2

Modified from Oji et al. 2010 [2].
OMIM number in [] (see <http://www.ncbi.nlm.nih.gov/omim>).

Table 2 Syndromic ichthyoses.

Disorder	Mode of inheritance	Gene(s)
X-linked ichthyosis syndrome		
X-linked recessive ichthyosis (XRI) syndromic forms [308700, 300500, 300533]	XR	STS (and others)
Ichthyosis follicularis with alopecia and photophobia (IFAP) syndrome [308205]	XR	<i>MBTPS2</i>
Conradi-Hunermann-Happle syndrome [302960] (CDPX2)	XD	<i>EBP</i>
Autosomal recessive ichthyosis syndromes with prominent hair abnormalities		
Netherton syndrome (NTS) [256500]	AR	<i>SPINK5</i>
Ichthyosis-hypotrichosis syndrome (IHS) [610765] (see ARCl1 in Table 1)	AR	<i>ST14</i>
Trichothiodystrophy (TTD) [601675]	AR	<i>ERCC2/XPD</i> <i>ERCC3/XPB</i> <i>GTF2H5/TTDA</i>
Trichothiodystrophy (non-congenital forms) [275550, 211390, 601675]	AR	<i>C7orf11/TTDN1</i>
Autosomal recessive ichthyosis syndromes with prominent neurological symptoms		
Sjögren-Larsson syndrome (SLS) [270200]	AR	<i>ALDH3A2</i>
Refsum's disease (HMSN4) [266500]	AR	<i>PHYH/PEX7</i>
Mental retardation, enteropathy, deafness, neuropathy, ichthyosis, keratoderma (MEDNIK) syndrome [609313]	AR	<i>AP1S1</i>
Autosomal recessive ichthyosis syndromes with fatal outcome		
Type 2 Gaucher disease type 2 [230900]	AR	<i>GBA</i>
Multiple sulfatase deficiency (MSD) [272200]	AR	<i>SUMF1</i>
Cerebral dysgenesis, neuropathy, ichthyosis, and palmoplantar keratoderma (CEDNIK) syndrome [609528]	AR	<i>SNAP29</i>
Arthrogyposis, renal dysfunction, cholestasis (ARC) syndrome [208085]	AR	<i>VPS33B</i>
Other syndromic ichthyoses		
Keratitis-ichthyosis-deafness (KID) syndrome [602450, 148210]	AD	<i>GJB2 (GJB6)</i>
Neutral lipid storage disease with ichthyosis [275630]	AR	<i>ABHD5</i>
Ichthyosis prematurity syndrome (IPS) [608649]	AR	<i>SLC27A4</i>

Q3 Modified from Oji et al. 2010 [2].
OMIM number in [] (see <http://www.ncbi.nlm.nih.gov/omim>).

- Is there pronounced erythroderma? As a symptom, erythroderma is nonspecific; it does, however, point in the direction of a rare congenital form of ichthyosis (example: congenital ichthyosiform erythroderma).
- Is/has the ichthyosis ever been associated with blisters? Important clue as to the presence of keratinopathic ichthyosis.
- Are there associated symptoms? Further symptom-oriented workup to rule out a syndromic ichthyosis variant.

Figures 1 and 2 present organizational charts with respect to differential diagnostic considerations.

4.3 Laboratory studies

In principle, the objective should be to establish the diagnosis as early as possible, in accordance with the parents. As the various tests necessary are associated with more or less invasive procedures (skin biopsy and/or drawing of blood), the time of the diagnostic workup must be based on the patient's clinical condition.

We recommend performing several diagnostic tests at the same time in order to avoid having to take multiple biopsies in more than one session. In this context, prior consultation with centers specialized in ichthyoses is advisable.

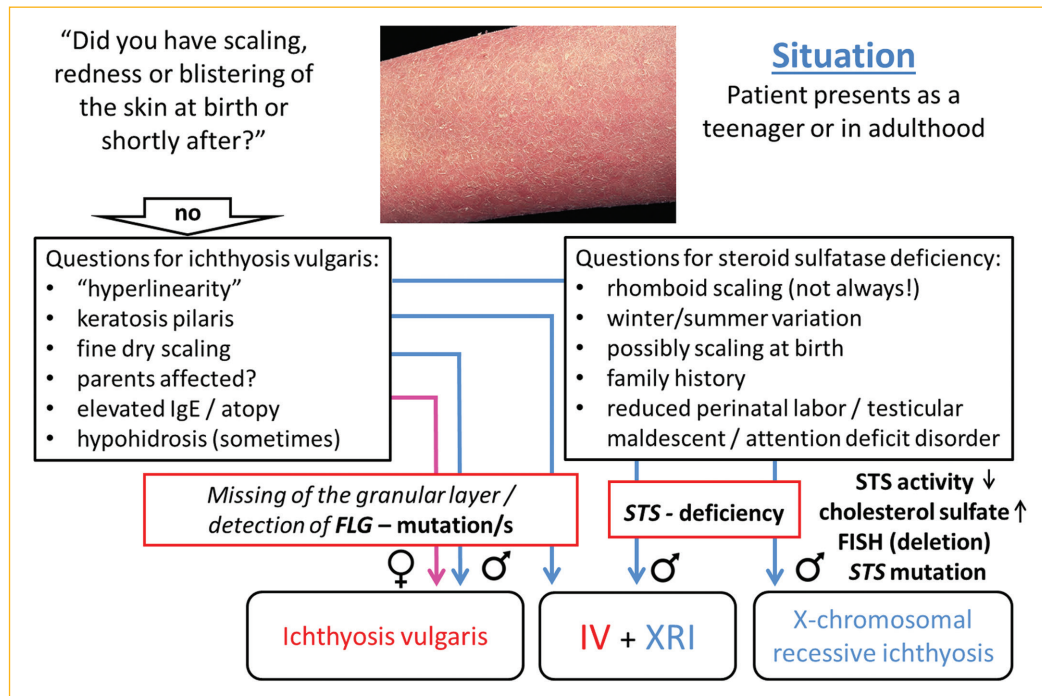


Figure 1 Diagnostic workup of common ichthyoses: patients with ichthyosis vulgaris (IV) or X-linked recessive ichthyosis (XRI) present in early childhood or even as adults as the onset of skin lesions is usually after birth in the first year of life. Apart from acquired ichthyosis, important differential diagnoses of “late-onset” ichthyosis include Refsum’s disease or a mild form of autosomal recessive congenital ichthyosis. The figure depicts a patient with ichthyosis vulgaris. *Abbr.*: STS, steroid sulfatase; FISH, fluorescence in situ hybridization; FLG, filaggrin.

(Examples are listed in Table S1 [online Supporting Information]). Further information on the various techniques can be obtained through the aforementioned treatment centers. The following diagnostic laboratory tests are available:

- ▶ *Histology and hair analyses*: morphological characteristics of ichthyosis vulgaris, epidermolytic ichthyosis, loricrin keratoderma, ichthyosis follicularis with alopecia and photophobia (IFAP syndrome), X-linked chondrodysplasia punctata type 2 (CDPX2), keratosis linearis with ichthyosis congenita and sclerosing keratoderma (KLICK), *peeling skin disease*. In combination with immunohistology: specific antigen mapping for ichthyosis vulgaris (filaggrin), Comèl-Netherton syndrome (LEKTI), *peeling skin disease* (CDSN). In case of Comèl-Netherton syndrome (trichorrhexis invaginata) and trichothiodystrophy (tiger-stripe pattern using a polarization filter, respectively low amount of cysteine), hair analyses provide key diagnostic clues.
- ▶ *Electron microscopy (criteria according to [6])*: very specific for the assessment of ichthyosis vulgaris, epidermolytic ichthyosis, harlequin ichthyosis (HI), KLICK, loricrin keratoderma and ichthyosis prematurity syndrome.


- Narrowing down of specific autosomal recessive congenital (ARCI) ichthyosis forms: *TGM1*, *PNPLA1*, *NIPAL4*
- ▶ *Measurement of functional activity*: fast frozen skin biopsy: in situ procedure to measure enzyme activity in collodion babies and/or ARCI (screening for transglutaminase-1 deficiency)
- ▶ *EDTA blood*: steroid sulfatase activity measurement in case of suspected X-linked recessive ichthyosis (XRI) or metabolite screening
- ▶ *Molecular genetic studies*: highly important for rare and severe forms of ichthyosis

4.4 Involvement of different medical specialties

The diagnosis and management of ichthyoses require an interdisciplinary approach [13, 14]. Neonatal ichthyoses necessitate close cooperation between neonatologists/pediatricians and dermatologists. In addition, timely evaluation by ophthalmologists and ENT specialists are indicated [15]. Depending on the specific disorder, an orthopedic and/or gastroenterological workup should also be carried out. Some children with ichthyosis require regular ergotherapy and/or physical therapy and benefit from sojourns at health resorts.

Challenges:

- temperature deregulation
- risk of dehydration
- risk of infection
- failure to thrive



Situation

Ichthyosis in a newborn

1.) Are there symptoms of a syndromic disease ?

- prematurity? IPS, NTS (HI)
- failure to thrive? NTS, TTD (HI)
- neurologic deficits?
- deafness? SLS, TTD
KID, MEDNIK
- abdominal ultrasound? NISCH
- skeleton CDPX2

Family history!

2.) Special aspects of the skin findings?

- skin blistering? KRT1, KRT10, KRT2
- erythroderma? ARCI, NTS, PSD, SLS
- collodion? LI, CIE (XRI)
- ectropion?
- ear deformation?
- hands/feet? **photos for special expert/s**
- hair ?

Q5 **Figure 2** Differential diagnostic considerations in congenital ichthyoses: whenever a neonate shows features of “collodion baby” or congenital ichthyosiform erythroderma, all differential diagnoses of congenital ichthyosis, including early manifestation of XRI, need to be considered. Some clinical features may provide clues as to specific nonsyndromic or syndromic types of ichthyosis. Crucial clues can frequently be gathered by appropriate photodocumentation and subsequent evaluation by an expert. The photograph shows a collodion baby. Possible diagnoses are boxed in red. *Abbr.:* ARCI, autosomal recessive congenital ichthyosis; CDPX2, X-linked chondrodysplasia punctata type 2; CIE, congenital ichthyosiform erythroderma; HI, harlequin ichthyosis; IPS, ichthyosis prematurity syndrome; IV, ichthyosis vulgaris; KID, keratitis-ichthyosis-deafness syndrome; KRT, keratin; LI, lamellar ichthyosis; MEDNIK, mental retardation-enteropathy-deafness-neuropathy-ichthyosis-keratoderma syndrome; NISCH, neonatal ichthyosis-sclerosing cholangitis syndrome; NTS, Comèl-Netherton syndrome; PSD, peeling skin disease; SLS, Sjögren-Larsson syndrome; TTD, trichothiodystrophy; XRI, X-linked recessive ichthyosis.

With respect to genetic counseling, parents ~~should go to~~ a genetic counseling office. Another option is to consult recognized ichthyosis experts in preparation for or commissioning of molecular genetic tests (specialized genetic counseling).

5 Treatment

5.1 Comments on the data available

With regard to the treatment of ichthyoses, there are only few methodologically high-quality studies available [12]; thus, the level of evidence primarily corresponds to “expert opinions” by specialists working at treatment centers with longstanding experience [3, 13, 16–22]. The development of novel forms of treatment is hampered by the circumstance that – given the rarity of severe ichthyoses in particular – conducting controlled studies proves to be exceedingly difficult, for example due to the long distances patients have to travel to get to the study centers. In Germany, the Network

for Ichthyoses and Related Keratinization Disorders (NIRK), which manages a central patients registry, was initiated in 2004 (www.netzwerk-ichthyose.de).

5.2 General objectives of symptomatic treatment options

Although there is currently no cure for genetic keratinization disorders, skin condition and quality of life can be significantly improved through optimized use of the wide range of therapeutic options available for the treatment of ichthyoses.

General therapeutic goals include the removal of hyperkeratosis and scales, making the skin smoother, facilitating the healing of rhagades, and preventing their occurrence [17]. These objectives can be achieved by hydrating the stratum corneum and minimizing the formation of hyperkeratosis. The following forms of treatment have become established practice and may be employed separately or in combination: balneotherapy, topical therapy with ointments, systemic

1 treatment. It should be pointed out that some patients, for
2 example those with epidermolytic ichthyosis or ~~Nether-ton~~
3 ~~syndrome~~, also require appropriate dressing material.

4 Specific information on certain forms of ichthyosis can
5 be found in chapter 7 of the long version of these guidelines
6 (online supporting information).

7 8 **5.3 Psychosocial and emotional support**

9
10 For parents, the diagnosis of ichthyosis means giving up their
11 notion of having a healthy child. The extreme emotional dis-
12 tress thus caused must be cushioned by the services offered
13 by contact persons at the hospital and subsequently by soci-
14 al pedagogues, psychologists, psychotherapists, and family
15 midwives [18, 23].

16 Grief and feelings of guilt on the part of the parents have
17 to be addressed in order to achieve the emotional stability
18 necessary to facilitate day-to-day life with an incurably and
19 chronically ill child, both with respect to the time-consuming
20 care and in terms of handling their social environment.

21 Contact to support organizations such as ~~Selbsthilfe~~
22 ~~Ichthyose e. V.~~ can provide critical relief to affected families
23 with regard to psychosocial and practical issues. At ~~Selbst-~~
24 ~~hilfe Ichthyose e. V.~~, they can find trained contact persons –
25 some specialized in different fields – not only for issues related
26 to care but also to everyday life with ichthyosis in all its facets.

27 28 **5.4 Physical therapy, ergotherapy,** 29 **and rehabilitation measures**

30
31 Depending on the age of those affected and particularly in the
32 Q6 case of children, regular physical therapy, possibly ~~in combi-~~
33 ~~nation with~~ ergotherapy, is frequently indicated. Tightening
34 of the skin in the area of the joints affects their free range of
35 motion. In the case of severe non-syndromic ichthyoses (includ-
36 ing harlequin ichthyosis, lamellar ichthyosis, epidermolytic
37 ichthyosis), the prevention of contractures is imperative; in
38 case of syndromic ichthyoses, such as Sjögren-Larsson syn-
39 drome, physical therapy may lead to clinical improvement.

40 In this context and with regard to general health aspects,
41 we recommend offering rehabilitation measures for ichthyos-
42 is patients at specialized rehabilitation centers that also pro-
43 vide facilities for balneotherapy. Insurance companies should
44 allow affected patients to stay at those rehabilitation centers
45 that have sufficient experience in the management of ichthyos-
46 is, and where it is more likely to meet other patients afflicted
47 with this rare disorder (psychosocial and emotional support).

48 49 **5.5 Balneotherapy**

50
51 Affected patients (~~Selbsthilfe Ichthyose e. V.~~) and treating
52 physicians (from rehabilitation centers, for example) have

accumulated a great deal of experience showing the effec-
tiveness of balneotherapy. Unfortunately, there is a lack of
methodologically high-quality studies on balneotherapy for
ichthyosis [21, 24].

The concern that the protective lipid barrier of the skin
might be “overstrained” by frequent bathing bears no rele-
vance in the context of ichthyosis treatment. The very oppo-
site is true: intensive bath therapy is very beneficial in severe
ichthyosis cases. Regular bathing – once or several times a
day – cleanses the skin, removes the residue of ointments,
and loosens scales. At the same time, the skin is hydrated.
Furthermore, hyperkeratoses are softened, which facilitates
their subsequent mechanical removal. Bathing in plain water
(or using a commercially available foam bath) usually fulfills
the various functions – cleansing, hydration, and softening
of the keratoses – sufficiently well. In the case of lamellar
ichthyosis, however, bath additives with a neutral pH hardly
have any effects (see section 200; keratolytic bath additives).
In preparation for bathing in the tub, a brief (5–15 minu-
tes) temperature-controlled steam bath or steam shower is
recommended; such pretreatment is meant to thoroughly hy-
drate the skin and soften the hyperkeratoses [17, 18]. In this
context, it is important to keep in mind that most individuals
affected have the tendency to develop hyperthermia due to
their decreased ability to perspire (which explains the advan-
tage of a cooler steam sauna) [17, 21].

5.5.1 Plain bath additives

Examples of emollient bath additives include oils (which re-
quire an additional emulsifying agent, though), spreading
oils and a large number of less common “secret recipes”, in-
cluding bran creams, sugar beet syrup/molasses, and whey.
The indication for the various bath additives is based on what
is predominantly required: lipid replacement or keratolysis
[17]. By contrast, oils – by themselves – frequently do not
have any keratolytic effects. They do, however, require great-
er effort in cleaning the bathtub, and are associated with the
risk of slipping (and falling). While they may also be directly
applied to the skin after the bath, their effects are only short-
lived if a towel is subsequently used for drying.

5.5.2 Salt

Bathing in water containing regular sodium chloride or salt
from the Dead Sea promotes hydration and keratolysis. How-
ever, patients with erythrodermic ichthyoses, Comèl-Nether-
ton syndrome, and ichthyoses with erosive areas, may experi-
ence uncomfortable burning sensations, which argues against
this therapeutic option. With most other forms of ichthyosis,
the burning sensation ceases once patients have gotten used
to the treatment. The salt concentration can then be increased

from 1 % up to 8 % without any complications. Given that higher salt concentrations cause corrosion of the plumbing system, this form of treatment is generally reserved for inpatient facilities or office-based dermatologists [17]. The salt concentration used for children should not exceed 3–4 %.

5.5.3 Keratolytic bath additives

The following bath additives have been shown to have keratolytic effects: sodium hydrogen carbonate (pharmacy-grade sodium bicarbonate powder or in the form of baking soda [available from wholesale bakery stores]), wheat starch (*amylum tritici*), rice starch (*amylum oryzae*) and corn starch (*amylum maydis*).

The increase in pH associated with the (alkaline) sodium hydrogen carbonate causes a softening and loosening of the hyperkeratosis – presumably through the increased activity of serine proteases. For adults, approximately 6 g of sodium bicarbonate per liter of bathwater – i.e. 3–4 handfuls (around 400 g) of sodium bicarbonate per bathtub – is necessary to adequately promote keratolysis. We generally recommend this treatment only for patients ≥ 1 year of age; for infants/toddlers, the concentration should be halved (approximately 3 g per liter). To simplify matters, commercially available baking soda can be used instead of sodium hydrogen carbonate [17, 18, 25].

5.6 Mechanical keratolysis

Following adequate softening of the keratoses in the bathtub (usually after 10–20 minutes) or immediately after pretreatment in the steam bath, various tools can be used to mechanically remove (with gentle pressure) the hyperkeratosis while repeatedly dousing the skin in the bath water. Suitable mechanical tools are commercially available. Tried and tested products include pumices or artificial stones, special “silk cloths from China”, “Moroccan or Turkish washing mittens” in various degrees of coarseness. Microfiber cloths in various qualities (available from drugstores or supermarkets) are useful for sensitive areas [18].

While supplementary mechanical keratolysis is superior to treatment solely with topical keratolytic agents, it does require a sufficient amount of practice. The frequency of use depends on the clinical condition (between once a day and once a week). The average amount of time needed for whole-body treatment in a patient with (well-controlled) severe ichthyosis is approximately 60–90 minutes [17].

5.7 Topical agents

Following water contact and in particular immediately after balneotherapy, topical lipid replacement has to be ensured in

order to maintain the hydration achieved by the bath. Additional keratolytic ingredients contained in the ointment act as a supplement to mechanical keratolysis, and can help counteract the recurrence of rhagades.

Topical preparations should not just be applied after every shower/bath. In severe ichthyosis cases, it is recommended to apply cream to the entire skin at least once or twice a day. If necessary, individual sites may have to be re-treated several times a day. With regard to commercially available ready-to-use preparations, the same products can be used as in children with atopic dermatitis; ichthyosis patients, however, tend to require an oilier base/formulation.

Given the higher rate of absorption and greater level of irritability in babies and infants, they should be treated with medication-free topical formulations [26]; the frequency of application in this patient group is roughly six to eight times daily [17, 21].

5.7.1 Urea

Urea was introduced into the treatment of ichthyosis by the Swedish physician Swanbeck in 1968 [27]. Considerable clinical experience has been gained not only at treatment centers but also by European and US patient support organizations. There is, however, only one single randomized controlled study in which the superiority of urea lotion (10 %) compared to the vehicle was demonstrated in ichthyosis patients [28].

Urea reduces epidermal proliferation, has barrier-regenerating, antimicrobial, and keratolytic effects, smoothens the skin, and facilitates the penetration of other active ingredients (depending on the base used). Extemporaneous formulations and finished products containing urea (5–10 %) improve the skin’s water-binding capacity and have keratolytic effects associated with low irritant potential. Urea can be combined with other active ingredients such as sodium chloride, lactic acid, or retinoic acid. The combination of urea 5 % and glycerine 5 % has good keratolytic effects while, at the same time, showing less irritant potential. While the hydrating and protective effects do not improve with urea concentrations greater than beyond 5 %, higher concentrations are required if the goal is to increase the keratolytic effects [29].

In children, urea should not be used in the first year of life. As regards inflammatory, erythematous, exfoliative ichthyoses, even low concentrations of urea frequently cause burning sensations. As the focus is less on keratolysis in these cases, one may resort to less irritant hydrating agents such as glycerine or dexpanthenol.

Based on the clinical presentation, it is frequently impossible to determine with certainty whether urea will be tolerated or not. Here, too, treatment therefore has to be based on individual tolerance.

5.7.2 Glycerine

Glycerine promotes the exfoliation of corneocytes and accelerates the breakdown of desmosomes by reducing desmoglein 1 [30]. It can be prescribed in any oil-in-water and amphiphilic base; concentrations of 5–10 % have proven useful (see section 230). The following officinal or new prescription formulary bases already contain glycerine 4.25 % and can serve as bases for formulations: non-ionic hydrophilic SR cream (NRF S.26) and lipophilic cream base (NRF 11.204) [29].

The use of glycerine as the only active ingredient has been shown to be particularly useful in ichthyosis vulgaris. In a double-blind randomized study, almost 70 % of all patients showed a response [31]; that percentage was lower in XRI (44 %) as well as congenital ichthyoses (43 %) [32].

5.7.3 Sodium chloride

Being hygroscopic, sodium chloride (NaCl) is a moisturizer. NaCl has a keratolytic effect at concentrations of 5–10 %; it is ideally used in a hydrophilic base. In extemporaneous formulations, NaCl is frequently present in crystalline structures of less than optimum quality, which is why such formulations are not commonly used [1, 2].

5.7.4 Lactic acid

Lactic acid (acidum lacticum) is a moisturizer that is more hygroscopic than glycerine or urea. It reduces keratoses and is well tolerated at concentrations of 5 % in amphiphilic cream bases. Higher concentrations are more irritant and thus less recommendable [1, 2]. In extemporaneous formulations, tolerance depends to a large degree on the lactic acid/sodium-lactate buffer [21]. In patients with severe barrier impairment, there is the theoretical risk of metabolic acidosis; lactic acid should therefore not be used in newborns.

5.7.5 Polyethylene glycol (Macrogol 400)

An oil-in-water emulsifying agent, polyethylene glycol (PEG), specifically Macrogol 400, has a hygroscopic effect; following penetration, it is able to hydrate the corneal layer. Given its hydrating effect without irritant potential, PEG (batch 400) shows mild keratolytic effectiveness. In amphiphilic bases, it can be used at concentrations of 20–30% [1, 29]. One aspect still subject to debate is whether percutaneous PEG absorption has the potential of changing the osmolarity of the blood. To date, it is unclear whether PEG should therefore not be used in the first and second year of life [33, 34].

5.7.6 Topical retinoids

Topical retinoids (tazarotene, retinoic acid, and tretinoin) are available as finished products (0.05–0.1 %) and in combination products with urea (usually tretinoin 0.03 % with urea 12 %), and can be freely prescribed in extemporaneous formulations. Topical retinoids have very good antikeratotic effects but, due to their irritant potential, they are generally only suitable for localized keratinization disorders or recalcitrant areas such as hands, feet, lower legs, and juxta-articular areas. *In case of long-term treatment of large areas, their teratogenic potential must be observed. As a matter of precaution, neither pregnant women nor any woman of child-bearing age must be treated with topical retinoids if she is not using a reliable method of contraception* [1, 29].

5.7.7 Salicylic acid (caution message)

Salicylic acid reduces intercellular cohesion and thus the thickness of the stratum corneum, and has a proteolytic effect. Salicylic acid penetrates the impaired skin barrier in patients with ichthyosis (especially if the pH is acidic), is absorbed, and can develop systemic effects. Salicylic acid leaves a deposit in the corneal layer that persists for up to 13 days after the last application. If the skin barrier is impaired, said deposit formation is less pronounced; however, more of the substance is absorbed, which results in toxic levels following repeated application. Acute toxic effects have been observed in children. The addition of “only” 3 % salicylic acid has been reported to cause fatalities within 72 hours due to metabolic acidosis, not only among newborns and babies but also among older children. *Consequently, despite its good keratolytic properties, salicylic acid should not be used for whole-body treatment of ichthyosis.* While localized topical treatment of hard-to-treat areas in older patients is generally possible, we do not recommend it [1, 13, 17, 18, 29].

5.7.8 α -hydroxycarboxylic acid (fruit acids)

Our expert group is currently not (yet) able to evaluate the risk-benefit profile of α -hydroxy acids (AHA). (To date, our own experience is too limited.) Several recent case reports suggest that the addition of AHA in the treatment of ichthyosis has a noticeable additive effect on creams containing urea (the effect corresponds to a mild AHA peeling). Affected individuals have reported that the frequency of this kind of topical treatment – following initially more frequent application compared to previously used ointments – can be significantly reduced over time. Due to their chemical properties, AHA are poorly suited for use in extemporaneous formulations (oxidation on contact with air). Patients can purchase

AHA creams or lotions as finished products, for example, those offered on the Internet.

Evidence of the presumed benefit of AHA, especially for lamellar ichthyosis, should be obtained in the context of methodologically high-quality studies. In the case of inflammatory ichthyoses, the irritant potential (due to marked keratolytic effects) has to be taken into account; hence, based on current experience, the use of AHA is not recommended. As there is no safety data available, we advise against AHA being used in the first years of life.

5.7.9 Vitamin E

In creams, vitamin E 5 % is only suitable as additive if the following points are observed: vitamin E is not photostable, especially in aqueous solutions, which is why an antioxidant such as butylated hydroxytoluene 0.05 % or α -tocopherol 0.1 % should be added. Vitamin E has an optimum pH of 4.5–5.

5.8 Topical preparations for specific sites

With respect to topical treatment, some site-specific peculiarities have to be observed [17]: on the scalp, preference should be given to water-soluble bases such as base cream DAC with keratolytic additives (urea 5–10 % and/or lactic acid 5 %). Therapeutic shampoos, with urea 5 % for example, are very useful. These shampoos should be left on the scalp for at least 5–10 minutes; in mild cases, they have adequate keratolytic effects.

Facial skin care is key to mitigating an existing ectropion. Treatment of the sensitive facial skin/eyelids should be done with glycerine-containing, low-dose keratolytic agents (urea of no more than 3 %) in an oil-in-water base in order to avoid irritation and folliculitis. In the majority of cases, sole emollient skin care without keratolytic agents is sufficient. Additives such as panthenol 5 % or vitamin E 5 % are suitable in this context.

Every form of topical treatment can be enhanced by occlusive dressings (film dressings). In recalcitrant areas – for example, in case of dark, firmly adherent keratoses on the neck in patients with XRI, localized keratoses associated with erythrokeratoderma, or over the joints in individuals with ARCI/EI – occlusive dressings are highly effective [17].

5.9 Systemic treatment

Acitretin is the only agent approved for the systemic treatment of ichthyoses. It inhibits keratinization and regulates cellular differentiation. With respect to the indication for its use, it is imperative to observe the summary of product

characteristics and weigh the benefits and adverse effects, considering that the underlying genetic disorder requires lifelong treatment. Apart from the contraindications (*the substance's teratogenicity in women*), it is important to consider the patient's compliance with regard to laboratory monitoring and, in case of long-term administration, X-ray monitoring). Even on systemic treatment, most ichthyoses will continue to require intensive, albeit somewhat simplified, topical treatment [22].

The improved ability to perspire can be a key reason in favor of using acitretin [35]. In general, systemic retinoids are more suitable for noninflammatory forms of ichthyosis. They are thus well suited for the treatment of lamellar ichthyosis and XRI but also for superficial epidermolytic ichthyosis or KRT10-associated epidermolytic ichthyosis (care should be taken with regard to increased induction of blistering). With certain restrictions, acitretin treatment is also suitable for Netherton syndrome (increased tendency for dermatitis).

While the acitretin dose can initially be gradually increased, the long-term goal is to reach a maintenance dose that is as low as possible [22]. In adults, a dose of no more than 1 mg/kg is adequate for the treatment of lamellar ichthyosis; for superficial epidermolytic ichthyosis or in KRT10-associated epidermolytic ichthyosis, no more than 0.5 mg/kg. However, a lower dose is generally used for long-term treatment (lamellar ichthyosis: 0.5 mg/kg; epidermolytic ichthyosis (with keratin 10 mutation): 0.2 mg/kg). It should be noted that retinoid therapy of epidermolytic ichthyosis (with KRT10 mutation) may be associated with marked disease exacerbation. An acitretin dose of 0.5 mg/kg (maximum: 1 mg/kg) is recommended for newborns with harlequin ichthyosis (see section 7.5). Long-term acitretin therapy should be avoided in children.

6 Genetic counseling

Following the diagnosis, ichthyosis patients and their relatives should be advised to seek genetic counseling in order to provide detailed information with respect to heredity and the risk of recurrence [2, 17].

If mutations have been identified in the context of severe forms of ichthyosis, counseling can address the possibility of prenatal diagnostic tests, for example, chorionic villus sampling (tenth to twelfth week of pregnancy) or amniocentesis (starting in the fourteenth week of pregnancy). In principle, preimplantation diagnosis will in the future also become an option in select cases. However, this has to be discussed with the diagnostic laboratory and the other centers involved.

The addresses of local counseling offices can be obtained from the Professional Association of German Geneticists: <http://www.bvdh.de/index.php>.

Comment on the methodology underlying the present guidelines

For methodology, conflicts of interest, and duration of validity, please refer to the long version of the guidelines online or to the AWMF website. This is an update of the guidelines published on April 17, 2008. Some passages were taken verbatim from the previous version.

References

- 1 Traupe H. The Ichthyoses. A Guide to Clinical Diagnosis, Genetic Counseling, and Therapy, Springer, Berlin, 1989.
- 2 Oji V, Tadini G, Akiyama M et al. Revised nomenclature and classification of inherited ichthyoses: results of the First Ichthyosis Consensus Conference in Sorèze 2009. *J Am Acad Dermatol* 2010; 63: 607–41.
- 3 Oji V, Metzke D, Traupe H. Mendelian Disorders of Cornification (MeDOC) In: Griffiths C, Barker J, Bleiker T et al. (ed): *Rook's Textbook of Dermatology*. 9th edition. Blackwell Publishing Ltd. 2016: 65.1–65.75.
- 4 Fischer J. Autosomal recessive congenital ichthyosis. *J Invest Dermatol* 2009; 129: 1319–21.
- 5 Oji V, Traupe H. Ichthyoses: Differential diagnosis and molecular genetics. *Eur J Dermatol* 2006; 16: 349–59.
- 6 Anton-Lamprecht I. Diagnostic ultrastructural of non-neoplastic diseases. In: Schmuth M, Martinz V, Janecke AR et al.: *Inherited ichthyoses/generalized Mendelian disorders of cornification*. *Eur J Hum Genet* 2013; 21: 123–33.
- 7 Haußer I. Ultrastructural characterization of lamellar Ichthyosis: a tool for diagnostic standardization. (Lecture) First World Conference on Ichthyosis, Münster 2007.
- 8 Traupe H, Fischer J, Oji V. Nonsyndromic types of ichthyoses – an update. *J Dtsch Dermatol Ges* 2014; 12: 109–21.
- 9 Schmuth M, Martinz V, Janecke AR et al. Inherited ichthyoses/generalized Mendelian disorders of cornification. *Eur J Hum Genet* 2013; 21: 123–33.
- 10 Elias PM, Williams ML, Crumrine D, Schmuth M. Inherited disorders of corneocyte proteins. *Curr Probl Dermatol* 2010; 39: 98–131.
- 11 Elias PM, Williams ML, Feingold KR. Abnormal barrier function in the pathogenesis of ichthyosis: therapeutic implications for lipid metabolic disorders. *Clin Dermatol* 2012; 30(3): 311–22.
- 12 Hernández-Martin A, Aranegui B, Martin-Santiago A, Garcia-Doval I. A systematic review of clinical trials of treatments for the congenital ichthyoses, excluding ichthyosis vulgaris. *J Am Acad Dermatol* 2013; 69: 544–9.
- 13 Oji V, Traupe H. Ichthyosis: clinical manifestations and practical treatment options. *Am J Clin Dermatol* 2009; 10: 351–64.
- 14 Ott H, Hütten M, Baron JM et al. Neonatal and infantile erythrodermas. *J Dtsch Dermatol Ges* 2008; 6: 1070–85.
- 15 Huang JT, Mallon K, Hamill S et al. Frequency of ear symptoms and hearing loss in ichthyosis: a pilot survey study. *Pediatr Dermatol* 2014; 31: 276–80.
- 16 Digiovanna JJ, Mauro T, Milstone LM et al. Systemic retinoids in the management of ichthyoses and related skin types. *Dermatol Ther* 2013; 26: 26–38.
- 17 Küster W. Ichthyosen: Vorschläge für eine verbesserte Therapie. *Dt Ärztebl* 2006; 103: A 1684–9.
- 18 Küster W (Überarbeitung Traupe H und Oji V). *Handbuch für Eltern und Betreuer von Kindern mit Ichthyose*. Hrsg.: Selbsthilfe Ichthyose e. V., 4. Auflage, Mittenwalde: Selbsthilfe Ichthyose e. V. 2015.
- 19 Oji V. Ichthyosen. In: Plewig G, Landthaler M, Burgdorf WHC et al. (eds): *Braun-Falco's Dermatologie, Venerologie und Allergologie*. 6. Auflage. Berlin, Heidelberg: Springer, 2012.
- 20 Prado R, Ellis LZ, Gamble R et al. Collodion baby: an update with a focus on practical management. *J Am Acad Dermatol* 2012; 67: 1362–74.
- 21 Traupe H, Burgdorf WHC. Treatment of ichthyosis – there is always something you can do! In memoriam: Wolfgang Küster. *J Am Acad Dermatol* 2007; 57: 542–7.
- 22 Vahlquist A, Gånemo A, Virtanen M. Congenital ichthyosis: an overview of current and emerging therapies. *Acta Derm Venereol* 2008; 88: 4–14.
- 23 Eilers E, Stieler K, Thies C et al. Harlequin ichthyosis – medical and psychosocial challenges. *Klin Padiatr* 2010; 222: 86–9.
- 24 Traupe H. Ichthyosis keeps surprising us. *Actas Dermosifiliogr* 2013; 104: 267–9.
- 25 Milstone LM, Scaly skin and bath pH: rediscovering baking soda. *J Am Acad Dermatol* 2010; 62: 885–6.
- 26 Wolf G, Hoeger PH. Dermatologische Basistherapie mit hypoallergenen und noxenfreien Externa im Kindesalter. *J Dtsch Dermatol Ges* 2009; 7: 50–61.
- 27 Swanbeck G. A new treatment of ichthyosis and other hyperkeratotic conditions. *Acta Derm Venereol* 1968; 48: 123–7.
- 28 Küster W, Bohnsack K, Rippke F et al. Efficacy of urea therapy in children with Ichthyosis. A multicenter randomized, placebo-controlled, double-blind, semilateral study. *Dermatology* 1998; 196: 217–22.
- 29 Gloor M. Moisturizer und andere die Hornschicht beeinflussende Wirkstoffe. Keratolytische bzw. proteolytische Wirkstoffe und Grundlagenbestandteile. In: Gloor M, Thoma K, Fluhr J: *Dermatologische Externotherapie unter besonderer Berücksichtigung der Magistralrezeptur*. 1. Auflage. Berlin, Heidelberg, New York: Springer, 2000: 105–32, 153–74.
- 30 Rawlings A, Harding C, Watkinson A et al. The effect of glycerol and humidity on desmosome degradation in stratum corneum. *Arch Dermatol Res* 1995; 287(5): 457–64.
- 31 Blanchet-Bardon C, Parmentier L, Pibourdin JM, Dupuy P. Etude comparative randomisée, en simple insu, évaluant l'efficacité et la tolérance de Dexeryl® crème dans le traitement symptomatique des ichthyoses. *Nouvel Dermatol* 19; 2000: 664–8.
- 32 Blanchet-Bardon C, Tadini G, Machado Matos M, Delarue A. Association of glycerol and paraffin in the treatment of

Guidelines

ichthyosis in children: an international, multicentric, randomized, controlled, double-blind study. <i>J Eur Acad Dermatol Venereol</i> 2012; 26: 1014–9.	34	Fligner CL, Jack R, Twiggs GA, Raisys VA. Hyperosmolality induced by propylene glycol. A complication of silver sulfadiazine therapy. <i>JAMA</i> 1985; 253: 1606–9.	1
33 Jakasa I, Verberk MM, Esposito M et al. Altered penetration of polyethylene glycols into uninvolved skin of atopic dermatitis patients. <i>J Invest Dermatol</i> 2007; 127: 129–34.	35	Haenssle HA, Finkenrath A, Hausser I et al. Effective treatment of severe thermodysregulation by oral retinoids in a patient with recessive congenital lamellar ichthyosis. <i>Clin Exp Dermatol</i> 2008; 33: 578–81.	2
			3
			4
			5
			6
			7
			8
			9
			10
			11
			12
			13
			14
			15
			16
			17
			18
			19
			20
			21
			22
			23
			24
			25
			26
			27
			28
			29
			30
			31
			32
			33
			34
			35
			36
			37
			38
			39
			40
			41
			42
			43
			44
			45
			46
			47
			48
			49
			50
			51
			52

Query/ Note to the author:

Q1: Author: Please confirm that given names (red) and surnames/family names (green) have been identified correctly.

Q2: Reference is missing.

Q3: Reference is missing.

Q4: Je Erkrankung? Ist je nach Erkrankung gemeint?

Q5: Please check Figure 2. 

Q6: „ggf. zusätzlichen oder einzelnen Ergotherapie“ Was ist mit „einzelnen“ Ergotherapie gemeint?

Q7: Das soll wohl heißen „nach dem ersten Lebensjahr“. Das erste Lebensjahr beginnt ja mit der Geburt.