



# University of HUDDERSFIELD

## University of Huddersfield Repository

Dinsdale, Graham, Moore, Tonia L., Manning, Joanne B., Murray, Andrea K., Atkinson, Ross A., Ousey, Karen, Dickinson, Mark, Taylor, Christopher and Herrick, Airane L.

Tracking digital ulcers in systemic sclerosis: A feasibility study assessing lesion area in patient recorded smartphone photographs

### Original Citation

Dinsdale, Graham, Moore, Tonia L., Manning, Joanne B., Murray, Andrea K., Atkinson, Ross A., Ousey, Karen, Dickinson, Mark, Taylor, Christopher and Herrick, Airane L. (2018) Tracking digital ulcers in systemic sclerosis: A feasibility study assessing lesion area in patient recorded smartphone photographs. *Annals of the Rheumatic Diseases*. ISSN 0003-4967

This version is available at <http://eprints.hud.ac.uk/id/eprint/34456/>

The University Repository is a digital collection of the research output of the University, available on Open Access. Copyright and Moral Rights for the items on this site are retained by the individual author and/or other copyright owners. Users may access full items free of charge; copies of full text items generally can be reproduced, displayed or performed and given to third parties in any format or medium for personal research or study, educational or not-for-profit purposes without prior permission or charge, provided:

- The authors, title and full bibliographic details is credited in any copy;
- A hyperlink and/or URL is included for the original metadata page; and
- The content is not changed in any way.

For more information, including our policy and submission procedure, please contact the Repository Team at: [E.mailbox@hud.ac.uk](mailto:E.mailbox@hud.ac.uk).

<http://eprints.hud.ac.uk/>

## **Tracking digital ulcers in systemic sclerosis – a feasibility study assessing lesion area in patient-recorded smartphone photographs**

Graham Dinsdale<sup>1</sup>, Tonia Moore<sup>2</sup>, Joanne Manning<sup>2</sup>, Andrea Murray<sup>1</sup>, Ross Atkinson<sup>3</sup>, Karen Ousey<sup>4</sup>, Mark Dickinson<sup>5</sup>, Christopher Taylor<sup>6</sup>, Ariane L Herrick<sup>1,7</sup>

1. Division of Musculoskeletal & Dermatological Sciences, University of Manchester, Salford Royal NHS Foundation Trust, Manchester Academic Health Science Centre, Manchester, UK.
2. Salford Royal NHS Foundation Trust, Salford, UK.
3. Wounds Research Group, Division of Nursing, Midwifery & Social Work, School of Health Sciences, University of Manchester, Manchester, UK.
4. Institute of Skin Integrity and Infection Prevention, University of Huddersfield, Huddersfield, UK.
5. Photon Science Institute, School of Physics and Astronomy, University of Manchester, Manchester, UK.
6. Centre for Imaging Sciences, Division of Informatics, Imaging & Data Sciences, University of Manchester, Manchester, UK.
7. NIHR Manchester Musculoskeletal Biomedical Research Centre, Manchester University NHS Foundation Trust, Manchester Academic Health Science Centre, Manchester, UK.

Corresponding author: Dr Graham Dinsdale, Clinical Sciences Building, Salford Royal Hospital, Stott Lane, Salford, M6 8HD. Email: [graham.dinsdale@manchester.ac.uk](mailto:graham.dinsdale@manchester.ac.uk)

Key message: Patient-recorded photographs of digital ulcers are feasible, and photographic measurements may help monitor healing.

Author contribution statement:

GD responsible for study design, data collection, data analysis, and editing and approval of manuscript.

TM, JM responsible for data collection, and editing and approval of manuscript.

AM responsible for study design, data analysis, and editing and approval of manuscript.

RA, KO, MD, CT, AH responsible for study design, and editing and approval of manuscript.

Competing interests:

All authors declare no conflicts of interest.

Sir,

Systemic sclerosis (SSc)-related digital ulcers (DU) are painful, and disabling[1-3], and digital ulcer burden is often the primary outcome measure in clinical trials of SSc-related digital vasculopathy[4]. This is despite several studies showing a lack of agreement between rheumatologists as to what constitutes a DU[5-8].

Objective outcome measures of SSc-related DUs for tracking change over time are therefore urgently required for clinical practice and research studies. The application of digital planimetry to clinical DU photographs has shown the possibility of fine-grained measurement of DU characteristics (area)[9]. Our aims were to: (1) demonstrate the feasibility of patients with SSc-related DUs/digital lesions photographing their lesions using smartphone cameras, and (2) use digital planimetry-style software analysis on images collected from patients to measure and track lesion area as a marker of healing or progression.

Patients with SSc-related digital lesions (judged to be ulcers by an experienced clinician) were asked to photograph their lesion(s) daily, using their own smartphone, for a maximum of 35 days. All patients gave written, informed consent. All patients were taking vasodilators, and 1 was on immunosuppressant therapy (methotrexate). The patients received normal clinical wound care throughout the study period, after which images were collected in-person, and stored securely for further analysis (see Figure 1 for examples).

Time and date stamps were extracted for each patient image sequence to accurately describe chronology. Images were loaded into custom digital planimetry software[9] and initially calibrated using a fixed-size object (often the finger width) to allow comparison between images in the sequence. For each image, the lesion area was measured by fitting an elliptical shape to the outline of the lesion by a single observer (Figure 1). Using the calibration information, areas from each image were finally normalised to the area measured in the first image in the sequence.

Image sequences were collected from four patients describing a total of seven lesions (one patient with three lesions, one patient with two lesions, two patients with one lesion). The median (range) sequence duration was 29 (13-35) days, and for number of images recorded/day 0.63 (0.31-1.00). The relative area time course for each lesion is shown in Figure 2. On average, lesion areas had, by study's end, reduced to 56% of the area measured on day 1, with six out of seven lesions reducing in size over the time course.

This pilot study confirms that it is feasible for patients to monitor their own lesions over an extended period (weeks) by taking photographs with their smartphone camera. Photographs were taken on approximately 2 out of every 3 days during the study period, suggesting patients were highly engaged in the process. Collected photographs were of analysable quality.

This study therefore suggests a potential new tool for monitoring of lesion status/healing, both in the clinical setting, and as an outcome measure in clinical trials of SSc-related digital vasculopathy. Further work involving larger numbers of patients is now required to validate measurements produced, and to improve data collection by integrating imaging into a smartphone application.

## Funding

This work was supported by MIMIT (Manchester: Integrating Medicine and Innovative Technology).

## References

1. Amanzi L, Braschi F, Fiori G, et al. Digital ulcers in scleroderma: staging, characteristics and sub-setting through observation of 1614 digital lesions. *Rheumatology (Oxford)* 2010;49(7):1374-82.
2. Matucci-Cerinic M, Krieg T, Guillevin L, et al. Elucidating the burden of recurrent and chronic digital ulcers in systemic sclerosis: long-term results from the DUO Registry. *Ann Rheum Dis* 2016;75(10):1770-6.
3. Hughes M, Herrick AL. Digital ulcers in systemic sclerosis. *Rheumatology (Oxford)* 2017;56(1):14-25.
4. Galluccio F, Allanore Y, Czirjak L, et al. Points to consider for skin ulcers in systemic sclerosis. *Rheumatology* 2017;56(suppl\_5):v67-v71.
5. Herrick AL, Roberts C, Tracey A, et al. Lack of agreement between rheumatologists in defining digital ulceration in systemic sclerosis. *Arthritis Rheum* 2009;60(3):878–82.
6. Baron M, Chung L, Gyger G, et al. Consensus opinion of a North American Working Group regarding the classification of digital ulcers in systemic sclerosis. *Clin Rheumatol* 2014;33(2):207–14.
7. Hughes M, Roberts C, Tracey A, et al. Does the clinical context improve the reliability of rheumatologists grading digital ulcers in systemic sclerosis? *Arthrit Care Res* 2016;68(9):1340-5.
8. Suliman YA, Bruni C, Johnson SR, et al. Defining skin ulcers in systemic sclerosis: systematic literature review and proposed World Scleroderma Foundation (WSF) definition. *J Scleroderma Relat Disord* 2017;2(2):115-120.
9. Simpson V, Hughes M, Wilkinson J, et al. Quantifying digital ulcers in systemic sclerosis: Reliability of digital planimetry in measuring lesion size. *Arthrit Care Res* 2017;Jun2:doi: 10.1002/acr.23300. [Epub ahead of print].

## Figure legends

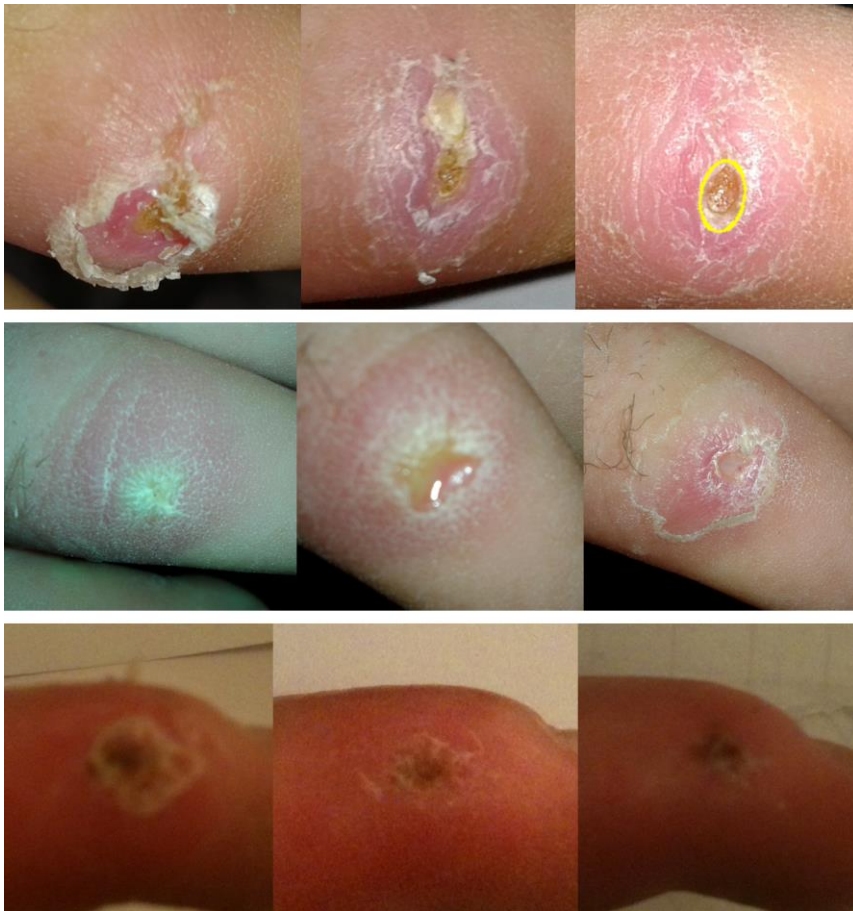

Figure 1. Selected examples of DU/lesion images taken from 3 sequences. Sequences demonstrate the varying quality of images captured by patients (particularly the bottom sequence where there are focus issues), although all were acceptable for further quantitative analysis. Top (L to R): days 1, 24, and 35; Middle (L to R): days 1, 4, and 12; Bottom (L to R): days 2, 7 and 18. Lesions are represented by sequences 4, 5 and 6 in Figure 2 (top to bottom respectively). Top right image includes example of fitted ellipse shape (yellow outline) from software analysis.

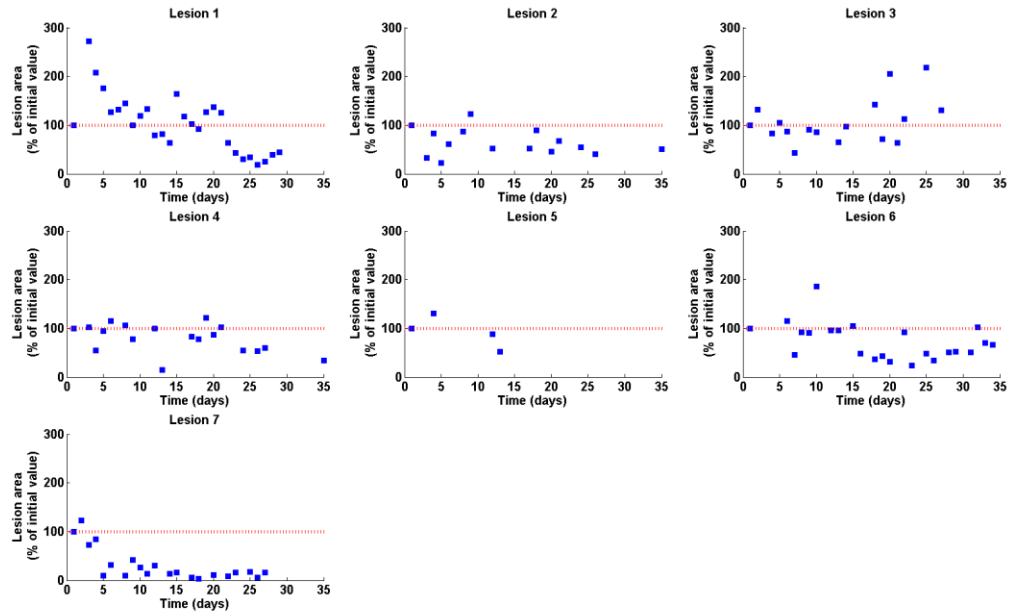


Figure 2. Relative area time course plots for each of 7 digital lesions. Dashed red lines indicate 100% area, relative to the area measured on day 1. Lesion areas all reduced except for lesion 3 (top right).