



# University of HUDDERSFIELD

## University of Huddersfield Repository

Vanita, V., Hejtmancik, J.F., Hennies, Hans C., Guleria, K., Nürnberg, P., Singh, D., Sperling, K. and Singh, J.R.

Sutural cataract associated with a mutation in the ferritin light chain gene (FTL) in a family of Indian origin

### Original Citation

Vanita, V., Hejtmancik, J.F., Hennies, Hans C., Guleria, K., Nürnberg, P., Singh, D., Sperling, K. and Singh, J.R. (2006) Sutural cataract associated with a mutation in the ferritin light chain gene (FTL) in a family of Indian origin. *Molecular Vision*, 12. pp. 93-99. ISSN 1090-0535

This version is available at <http://eprints.hud.ac.uk/id/eprint/28812/>

The University Repository is a digital collection of the research output of the University, available on Open Access. Copyright and Moral Rights for the items on this site are retained by the individual author and/or other copyright owners. Users may access full items free of charge; copies of full text items generally can be reproduced, displayed or performed and given to third parties in any format or medium for personal research or study, educational or not-for-profit purposes without prior permission or charge, provided:

- The authors, title and full bibliographic details is credited in any copy;
- A hyperlink and/or URL is included for the original metadata page; and
- The content is not changed in any way.

For more information, including our policy and submission procedure, please contact the Repository Team at: [E.mailbox@hud.ac.uk](mailto:E.mailbox@hud.ac.uk).

<http://eprints.hud.ac.uk/>



# Sutural cataract associated with a mutation in the ferritin light chain gene (*FTL*) in a family of Indian origin

Vanita Vanita,<sup>1</sup> James Fielding Hejtmancik,<sup>2</sup> Hans Christian Hennies,<sup>3,4</sup> Kamlesh Guleria,<sup>1</sup> Peter Nürnberg,<sup>3,4</sup> Daljit Singh,<sup>5</sup> Karl Sperling,<sup>6</sup> Jai Rup Singh<sup>1</sup>

<sup>1</sup>Centre for Genetic Disorders, Guru Nanak Dev University, Amritsar, India; <sup>2</sup>National Eye Institute, National Institute of Health, Bethesda, MD; <sup>3</sup>Cologne Center for Genomics and Institute for Genetics, University of Cologne, Germany; <sup>4</sup>Gene Mapping Center, Max Delbrück Center for Molecular Medicine, Berlin, Germany; <sup>5</sup>Dr. Daljit Singh Eye Hospital, Amritsar, India; <sup>6</sup>Institute of Human Genetics, Charité Humboldt-University, Berlin, Germany

**Purpose:** The molecular characterization of 27 members of an Indian family, with 13 members in four generations, affected with Y-sutural congenital cataract.

**Methods:** Detailed family history and clinical data were collected. A genome-wide scan by two-point linkage analysis using more than 400 microsatellite markers in combination with multipoint lod score and haplotype analysis was performed. Mutation screening was carried out in the candidate gene by bi-directional sequencing of amplified products.

**Results:** A maximum two-point lod score of 6.37 at  $\theta=0.00$  was obtained with marker D19S879. Haplotype analysis placed the cataract locus to a 5.0 cM region between D19S902 and D19S867, in close proximity to the L-ferritin light chain gene (*FTL*) on chromosome 19q13.3. Hematological tests in two affected individuals showed very high levels of serum ferritin without iron overload leading to the diagnosis of hyperferritinemia-cataract syndrome. Mutation screening in *FTL* identified a G>A change at position 32 (c.-168G>A) in a highly conserved 3 nucleotide motif that forms a loop structure in the iron responsive element (IRE) in the 5'-untranslated region (5'-UTR). This nucleotide alteration was neither seen in any unaffected member of the family nor found in 50 unrelated control subjects.

**Conclusions:** The present study is the first report of a Y-sutural congenital cataract mapping to 19q13.3. The mutation observed in *FTL* in this family highlights the phenotypic heterogeneity of the disorder in relation to the genotype as the identical mutation (32 G>A) has previously been reported in two Italian families with entirely different phenotypes. It is also the first report of hereditary hyperferritinemia-cataract syndrome in a family of Indian origin.

Congenital cataract is a clinically and genetically highly heterogeneous eye lens disorder. Its incidence is estimated to be 2.2 to 2.49 per 10,000 live births [1,2]. One-third of the cases show a positive family history [3], usually suggesting an autosomal dominant mode of inheritance [4,5]. It may occur as an isolated eye anomaly or as a part of a multisystem syndrome.

Lens sutures are the lines at anterior and posterior poles of the embryonic lens nucleus where growing secondary fiber cells from the equator migrate and meet. Sutures start to appear at the eighth to ninth weeks of fetal life. The addition of more cell layers till birth forms the suture plane with a symmetrical Y-pattern and a symmetrical inverted Y-pattern at respective anterior and posterior sections of the lens [6]. After birth, suture formation becomes complex and irregular due to fundamental changes that occur in the lens fibers differentiation [7]. Abnormal development of sutures has been found to be associated with specific types of cataracts [8]. A cataract is classified as sutural when the opacity affects the whole or part of either one or both sutures of the lens. So far, sutural cataract, in association with other lens opacities, has been mapped

at 1p36 [9], 3q (*BFSP2*) [10-12], 15q [13], 16q22 (*HSF4*) [14], 17q (*CRYBA1*) [15], 22q (*CRYBB1*, *CRYBB2*) [16,17], and in syndromal cases at 14q13-21 (craniolenticulosutural-dysplasia syndrome) [18] and on the X chromosome (Nance-Horan syndrome gene, *NHS*) [19].

Hereditary hyperferritinemia-cataract syndrome (HHCS; OMIM 600886) is an autosomal dominant disorder characterized by early onset bilateral nuclear cataract in association with a manyfold increase in L-ferritin levels in blood serum and in tissues such as lymphocytes, liver, and lenses in the absence of iron overload [20-22]. Under normal conditions, synthesis of ferritin is regulated at the translational level by iron availability. During low iron status, high affinity interaction between trans-acting iron regulatory proteins (IRPs) and the iron responsive element (IRE) in the 5'-untranslated region (5'-UTR) of L-ferritin mRNA prevents iron sequestration by blocking ferritin translation. In cases of abundant cellular iron availability, formation of 4Fe-4S clusters within IRPs inhibits their binding to the IRE and allows abundant ferritin translation [20,22-24]. So far, 28 different mutations have been found in the 5'-UTR of the L-ferritin gene, resulting in reduced affinity for IRPs and hence increased synthesis of L-ferritin.

We came across a four generation family affected with bilateral congenital cataract at the Dr. Daljit Singh Eye Hos-

Correspondence to: Dr. Vanita Vanita, Centre for Genetic Disorders, Guru Nanak Dev University, Amritsar-143005, Punjab, India; Phone: +0183-2258802-09, ext. 3277 or 3279; FAX: +0183-2258863; email: vanita\_kumar@yahoo.com

pital, Amritsar, India. A genome-wide scan by two-point linkage analysis using more than 400 microsatellite markers and further multipoint and haplotype analysis placed the cataract locus within a 5.0 cM region between markers D19S902 and D19S867 on chromosome 19q13. Since *FTL* lies within the mapped interval, and because of its association with HHCS, hematological tests were performed in two patients. These indicated high levels of ferritin in the serum without iron overload. Sequencing of *FTL* showed a G>A change in the 5'-UTR at position 32 from the transcription start site, in a highly conserved three-nucleotide motif that forms the IRE bulge. This is the first report of HHCS in a family of Indian origin.

**METHODS**

**Family description:** The index case, a five-year-old child, was diagnosed as having bilateral sutural cataract (Figure 1). The family history revealed 13 affected members in four generations (Figure 2). The detailed ophthalmological examination, which included slit lamp examination and photography of affected lenses, performed on 27 members of the family, revealed 13 members who were bilaterally affected (some had a history of cataract extraction in childhood) and 14 individuals (including four spouses) who were unaffected.

**Phenotype description:** In all affected individuals the opacities were confined to the Y-sutures (Figure 1). However, this sutural cataract was peculiar in appearance as the opaci-

ties were flat and wide, nonuniform in width, and appeared to be composed of small round and oval segments, superimposed upon each other near the edges. It appeared like a pile of coins. This coin-like character was seen in the primary Y-sutures and in its divisions. Both anterior and posterior lesions were similar in appearance. In optical sections, the location of the opaci-




Figure 1. Photograph (3-D lens) of a patient taken through a slit lamp. The phenotype is Y-sutural as both the anterior and posterior inverted Y-sutures are severely affected. No nuclear component is involved, and there is no opacity evident in the cortex of the lenses. The opacity appears to be made up of a compilation of coins.

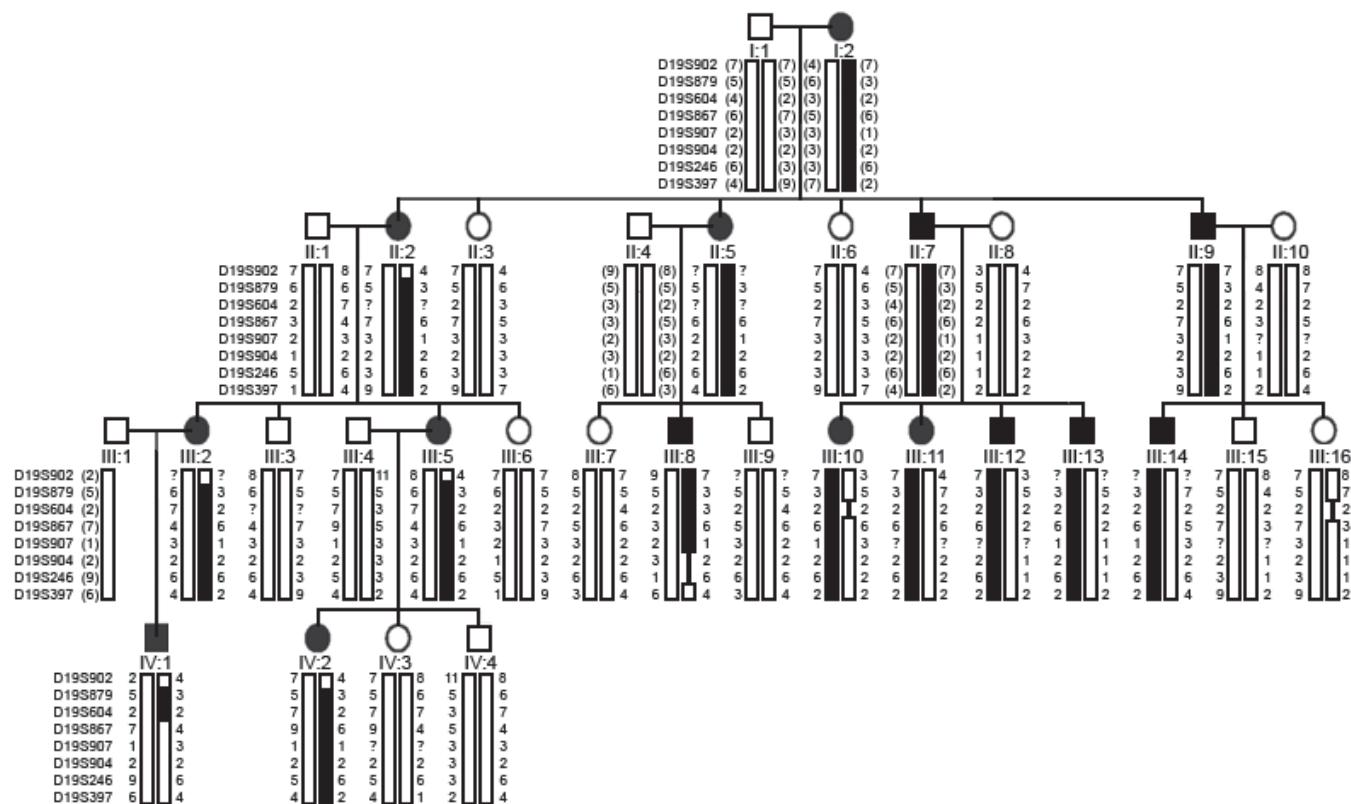


Figure 2. Haplotype analysis of a sutural cataract family with chromosome 19 markers. Sequence of markers is from centromere to telomere. Blackened bars indicate the affected haplotype. Inferred haplotypes are in parentheses. Recombination events seen in individuals II:2 and IV:1 place the disease gene locus between markers D19S902 and D19S867.

ties was between the nucleus and the surrounding cortex, at some distance from the anterior and posterior capsules. There were no additional opacities in the lens. The nucleus and the periphery were clear. In short, this phenotype may be described as a Y-sutural cataract composed of coin-like segments.

**Genotyping and linkage analysis:** Informed consent was obtained from each individual studied. This study was approved by the ethics review board of the Guru Nanak Dev University, consistent with the provisions of the Declaration of Helsinki. Blood was drawn and DNA isolated by standard methods. A genome-wide search with more than 400 microsatellite markers (Genethon linkage map) [25] was done on DNA samples of all 27 ophthalmologically examined individuals (13 affected and 14 unaffected, including four spouses). Microsatellites were amplified in singleplex reactions by touchdown PCR (MJ-Research, Watertown, MA) using fluorescent-labeled primers following standard methods. Polymerase chain reaction (PCR) products were pooled and denatured at 95 °C for 1 min and electrophoresed on 96-capillary automated DNA sequencers (MegaBACE 1000, Amersham, Freiburg, Germany). Genotyping was done with the use of the software Genetic Profiler version 1.5 (Amersham). Autosomal dominant inheritance with a disease gene frequency of 0.0001 and complete penetrance of the trait was assumed. Recombina-

tion frequencies were considered equal between males and females. Two-point linkage analysis was carried out with MLINK from the LINKAGE program package [26], and multipoint analysis was carried out using Genehunter [27]. Autosomal dominant inheritance was assumed with a reduced penetrance of 98% and a phenocopy rate of 0.5%.

**Hematological tests:** After informed consent was obtained, fresh blood was drawn from two affected individuals (II:9, III:12; Figure 2) and sent to the Clinical Reference Laboratory (SRL Ranbaxy, Mumbai Maharashtra (MH), India) for measuring serum ferritin, serum iron, total iron binding capacity (TIBC), and transferrin levels.

**Mutation analysis:** Four pairs of primers (Table 1) were designed from intronic regions to amplify the coding regions and splice sites of *FTL* (GenBank NM\_000146.3 and NC\_000019.8). Genomic DNA from two affected and one unaffected individuals were amplified. Amplification was carried out in 25 µl reactions containing 100 ng genomic DNA, 10 pmoles each of forward and reverse primers, 200 µM dNTP, 10X PCR buffer, 1.5 mM MgCl<sub>2</sub>, and 0.25 U Taq DNA polymerase (AmpliTaq Gold; ABI, Foster City, CA). Amplification conditions consisted of an initial denaturation step at 95 °C for 5 min, followed by 35 cycles consisting of a denaturation step at 95 °C for 45 s, annealing step for 30 s at 57 °C, and an extension at 72 °C for 45 s, followed by a final extension step at 72 °C for 10 min. PCR products were purified using a PCR product purification kit (QIAquick; Qiagen, Valencia, CA). Purified PCR products were sequenced bidirectionally using the ABI BigDye™ Terminator Cycle Sequencing Ready Reaction Kit version 3.1 (ABI) for a 10 µl final volume, containing 5.0 µl purified PCR product, 4.0 µl BigDye Terminator ready reaction mix and 3.2 pmoles of primers. Cycling conditions were 95 °C for 2 min, 25 cycles at 95 °C for 30 s, 52 °C for 15 s, and 60 °C for 4 min. The sequencing reaction products were purified by the isopropanol precipitation method (ABI protocol), suspended in 10 µl of formamide (Hi-Di-Formamide; ABI), denatured at 95 °C for 5 min, and electrophoresed on an ABI 3100 Genetic Analyzer. Sequencing results were assembled and analyzed using the SeqMan II program of the Lasergene package (DNA STAR Inc., Madison, WI).

**TABLE 1. PRIMER SEQUENCES FOR AMPLIFICATION OF EXONIC REGIONS OF FERRITIN LIGHT CHAIN POLYPEPTIDE (*FTL*)**

Exon	Sequence (5'-3')	PCR product size (bp)	Annealing temperature (°C)
1F	CCTATGTGCTCCGGATTGGTCA	549	57
1R	GTAACAGAGGGCGGAGTCC		
2F	CACCTCCGGCCCTCACTGC	385	57
2R	TGAGTTCGGTCTTGTGAGCCCT		
3F	GGACAGGGTGCGGAGAGTGATAAA	361	57
3R	TTCCTTCAGAGCCTCATTTCACAC		
4F	TCCTTCAGAGCCTCATTTCACACC	445	57
4R	TGGTGTGGAAGATGAGGTGGGAT		

Shown are primers for PCR (polymerase chain reaction) and sequencing of *FTL*.

**TABLE 2. TWO-POINT LOD SCORES FOR LINKAGE BETWEEN THE DISEASE LOCUS AND CHROMOSOME 19 MARKERS**

Marker	IMD (cM)	LOD Scores at $\theta$								
		0.00	0.001	0.01	0.05	0.10	0.15	0.20	0.30	0.40
D19S902	2.7	-5.356	0.440	1.388	1.854	1.851	1.710	1.503	0.984	0.430
D19S879	0.1	6.370	6.360	6.267	5.844	5.291	4.708	4.091	2.740	1.230
D19S604	2.2	2.249	2.245	2.210	2.051	1.841	1.617	1.383	0.890	0.402
D19S867	0.5	2.393	2.462	2.785	3.030	2.900	2.641	2.313	1.521	0.607
D19S907	0.1	3.084	3.080	3.046	2.874	2.623	2.338	2.022	1.303	0.510
D19S904	0.0	1.219	1.216	1.192	1.085	0.947	0.806	0.661	0.370	0.114
D19S246	4.0	3.201	3.195	3.137	2.873	2.532	2.178	1.809	1.034	0.305
D19S397	4.0	1.343	1.489	2.196	2.965	3.061	2.908	2.631	1.835	0.800

This table summarizes the two-point LOD scores for chromosome 19q13.3 around the *FTL* locus. The highest observed LOD score was 6.37 at  $\theta=0.0$  for marker D19S879. Intermarker distances (IMD) are based on the Genethon linkage map [25].

**RESULTS**

**Linkage analysis:** In a genome-wide scan using more than 400 markers, we initially obtained positive two-point lod scores of 1.977 at  $\theta=0.001$  with marker D19S178 and of 3.201 at  $\theta=0.000$  with marker D19S246. Further analysis with more markers in this region on chromosome 19 gave a maximum lod score of 6.37 at  $\theta=0.000$  with marker D19S879 (Table 2). Multipoint analysis carried out with more markers from this region also supported the linkage with the same maximum lod score of 6.37 with D19S879 (data not shown).

**Haplotype analysis:** Haplotypes were constructed for the markers analyzed on chromosome 19 (Figure 2). Recombination events were detected in affected individuals II:2, III:8, and IV:1. Individual II:2 was recombinant at marker D19S902, individual III:8 was found to be recombinant at marker D19S397, while individual IV:1 was found to be recombinant at marker D19S902, as seen in his mother and grandmother, and markers telomeric to D19S867. Cosegregation was observed in all affected individuals for markers D19S879 and D19S604, indicating that the disease locus lies in this interval. The cataract locus was thus mapped to a 5.0 cM region

between D19S902 and D19S867, which corresponds to a region on chromosome 19q13.3.

**Hematological analysis:** The candidate gene *FTL* lies within the mapped critical interval and is pathogenetically involved in HHCS. Therefore, we performed hematological analyses in two affected individuals II:9 and III:12 (Figure 2). They showed very high serum ferritin levels (2283.1 and 1638.7  $\mu\text{g/l}$ , respectively; Table 3) in comparison to the control levels (range: 22-322  $\mu\text{g/l}$ ). Serum iron, TIBC, and its relative saturation, serum transferrin, and transferrin saturation levels were within normal range in patient II:9. In patient III:12, the levels of TIBC were slightly higher and the transferrin saturation lower than in the controls. These findings indicated that these individuals had HHCS.

**Mutation analysis:** Sequencing of *FTL* in two affected individuals (II:9 and III:12) showed a heterozygous change G>A (Figure 3) at position 32 from the transcription start site (c.-168G>A). This position belongs to the IRE in the 5'-UTR of *FTL*. All other affected family members tested also showed this nucleotide change. This alteration was neither seen in any unaffected member of the family nor found in 50 unrelated

**TABLE 3. HEMATOLOGICAL DATA OF THE CATARACT PATIENTS INVESTIGATED**

Patient ID	Serum iron levels ( $\mu\text{g/dl}$ )	Total iron binding capacity ( $\mu\text{g/dl}$ )		Transferrin saturation (%)	Serum transferrin (mg/dl)	Serum ferritin levels ( $\mu\text{g/dl}$ )
		unsaturated	saturated			
73	76	249.0	325	23.4	261	2283.1
85	37	377.0	414	8.9	307	1638.7
Reference range	35-140	130-375	245-400	13-45	200-400	22-322

Shown here are the serum iron, total iron binding capacity, transferrin saturation, and serum ferritin levels in patients with congenital cataract. Very high levels of serum ferritin (1638.7 and 2283.1  $\mu\text{g/l}$ ) were observed in patients as compared to the reference range.

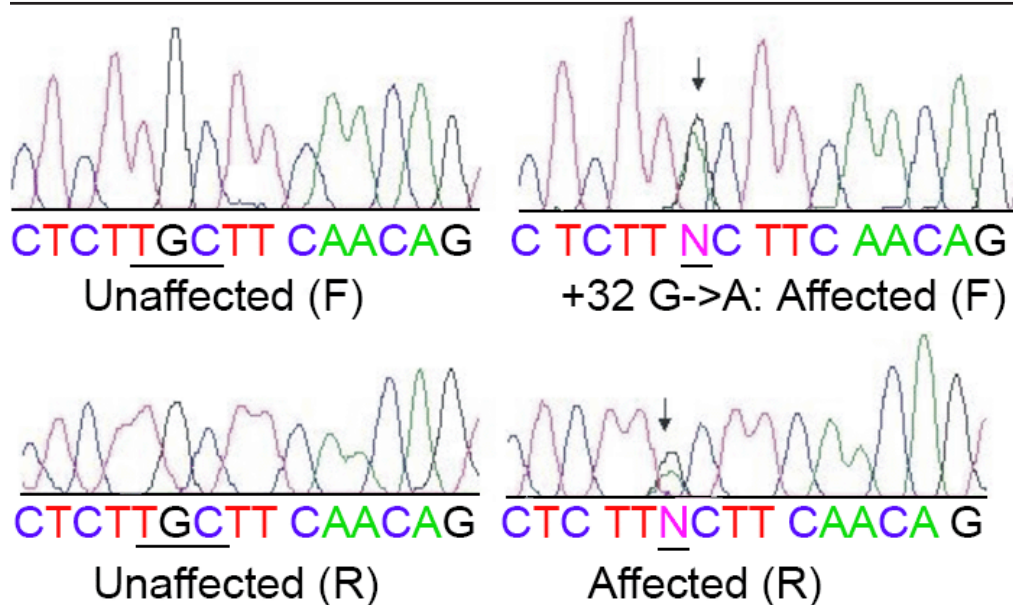


Figure 3. DNA sequence of a part of ferritin light chain polypeptide in an unaffected and an affected individual. Electropherogram showing a part of the IRE (iron responsive element) sequence of *FTL* (ferritin light chain polypeptide) in an unaffected (forward and reverse strands) and an affected family member (forward and reverse strands; individuals III:3 and IV:1). A heterozygous change G>A in the 5'-untranslated region (5'-UTR) at position 32 from the transcription start (c.-168G>A) is indicated by arrows.

control subjects (data not shown). Apart from this, a known polymorphic change, TTG to CTG in codon 55 in exon 2 of *FTL* (both coding for leucine), was observed in affected and unaffected individuals (data not shown).

### DISCUSSION

This study is the first report of a Y-sutural congenital cataract mapping to 19q13.3. The opacities were present bilaterally since birth in the affected members who underwent cataract surgery during the first decade of life. Both Y-sutures were severely affected without involvement of any other lens components. The lens nucleus, cortex, and periphery were clear. Two affected individuals, in whom hematological tests were undertaken, showed very high levels of serum ferritin without iron overload, indicating HHCS. This was confirmed by mutation screening in *FTL* showing a disease-causing G>A mutation in the 5'-UTR at position 32 of exon 1 in all affected individuals. This mutation, also known as the Pavia-1 mutation, has been reported in two Italian families in association with nuclear and bilateral cataracts, respectively [24,28]. The Indian family described here with an identical mutation differs from the Italian families in having an entirely different cataract phenotype, in the age of cataract onset, and in the levels of serum ferritin. To our knowledge, this is the first report of HHCS in a family of Indian origin, after previous reports of HHCS from Europe, Australia, and the USA.

So far, at least 28 mutations have been reported in the 5'-UTR of *FTL*; some occurred in the loop (5'-CAGUG-3' at positions 39 to 43), while others affected the bulge (5'-UGC-3' at positions 31 to 33) or stem of the IRE. Most of these mutations alter the structure of the IRE thus either abolishing or significantly decreasing the affinity binding of IRPs. This results in constitutive upregulation of L-ferritin in the serum and body tissues [29,30]. It has been reported that nucleotide 32G is important for IRE function in vivo and for high affinity RNA-protein interaction in vitro [31]. On the basis of a thermodynamic analysis, it has been revealed that mutations in the IRE either change its stability and secondary structure or disrupt the IRP-IRE recognition site [32].

Cazzola et al. [24] tried to establish a relationship between the identified mutations, the serum-ferritin levels, and the severity of the cataract. They observed that mutations within the IRE loop sequence resulted in the highest ferritin levels (1200-2700 µg/l) with severe cataracts (marked loss of visual acuity in the first decade with some individuals requiring cataract surgery). Mutations in the IRE bulge caused mild cataract (visual acuity corrected with the use of appropriate eye glasses) with ferritin levels being in the range of 950-1900 µg/l. The nucleotide changes in the lower stem of the IRE resulted in lowest levels of ferritin (350-650 µg/l) with asymptomatic cataract (no effect on visual acuity). These findings were confirmed by Mumford et al. [22], who showed

**TABLE 4. MUTATIONS IN IRE BULGE (5'-UGC-3' AT POSITIONS 31 TO 33) OF *FTL* POLYPEPTIDE IN RELATION TO FERRITIN LEVELS AND CATARACT TYPE**

Nucleotide change	Origin of family	Serum ferritin (µg/l)	Cataract diagnosis	Cataract type/severity	Reference
32G>C	USA	793-2350	Childhood	Bilateral*	[38]
32G>C	Italy	1270-1450	18 months	Bilateral*	[39]
32G>C	English	2000-2898	9 weeks	Bilateral*	[40]
32G>T	Paris	1025-2264	Late childhood/adulthood	Mild cataract*	[31]
32G>T	Paris	734-1362	3-40 years	Pulverulent	[34]
32G>T	Australia	1554	2 years	Bilateral*	[41]
32G>A	Italy	950-1900	Childhood	Nuclear (severe cataract)	[24]
32G>A	Italy	1100-1275	7-18 years	Bilateral* mild to severe	[28]
32G>A	India	1638-2283	At birth	Severely affected Y-sutural, without nuclear opacities	Present study
33C>T	Spain	989-1770		Mild bilateral* cataract during 1st decade, except in proband	[33]
33C>T	Italy	653-1392	9-18 years		[34]
33C>T	USA	1300-1440	5 years	Bilateral*	[36]
33C>A	Paris	1000			[42]

This table shows the identified mutations in the bulge region of the iron responsive element (IRE) in the 5' UTR (untranslated region) of *FTL* (ferritin light chain polypeptide) in relation to origin of family, serum ferritin levels, age at diagnosis of cataract, and its phenotype. In the "Nucleotide change" column, the numbering starts from the transcription start site (GenBank NM\_000146.3). The asterisk indicates that no exact phenotype of opacity was described by the authors.

that mutations near the apex of the IRE resulted in higher serum ferritin concentrations and denser cataracts, and by Balas et al. [33], who observed mild cataracts associated with mutations in the bulge region. However, not all mutations reported in this region follow a simple genotype-phenotype correlation (Table 4).

Balas et al. [33], Girelli et al. [34], and Perez de Nanclares et al. [35] reported that lens opacities in their HHCS patients were not detectable at birth and manifested in an age-dependent manner. In the present family, lens opacities were prominent since birth, with both Y-sutures being severely affected. The patients needed early cataract surgery within their first decade of life.

A 5-20 fold higher accumulation of L-ferritin in serum and tissues has been observed in HHCS cases, which has no evident effect on the body iron status but is often associated with early onset cataract. Two mechanisms have been proposed for this association of cataract with hyperferritinemia. A change in the L- and H-subunit ratio of ferritin composition may cause an increase in free iron and reactive oxygen, resulting in oxidative damage of the lens and cataract formation. Alternatively, cataract may be the result of lens protein aggregation caused by intracellular ferritin. Thus, Brooks et al. [36] reported light diffracting deposits of ferritin crystals in HHCS cataractous lenses, and Mumford et al. [37] found that HHCS lenses contain crystalline deposits of L-ferritin. However, Levi et al. [21] reported that ferritin in HHCS lenses was readily soluble without forming any aggregates in vitro and suggested that ferritin precipitation is not the primary cause of lens opacity.

In summary, large intragenic heterogeneity and phenotypic variability with respect to severity and type of cataract, age of onset, and serum ferritin levels has been observed in HHCS. This is illustrated in our patients and in those from two Italian families [24,28]. They share the same *FTL* mutation (32G>A) but show clear differences in the type of cataract, the age of onset, and the serum ferritin levels. Thus, apart from the pathogenetic mutation, other genetic or even environmental factors must play a significant role in disease manifestation. The analysis of serum ferritin levels is therefore mandatory in individuals with congenital cataract to establish the correct diagnosis HHCS.

#### ACKNOWLEDGEMENTS

We wish to thank the patients and their relatives for their cooperation. This work was in part supported by grant number DBT/BT/IC/71/89/Pt sanctioned to JRS, INI 331 from BMBF to KS, and SR/FT/L-91 from DST to VV.

#### REFERENCES

- Rahi JS, Dezaux C, British Congenital Cataract Interest Group. Measuring and interpreting the incidence of congenital ocular anomalies: lessons from a national study of congenital cataract in the UK. *Invest Ophthalmol Vis Sci* 2001; 42:1444-8.
- Wirth MG, Russell-Eggitt IM, Craig JE, Elder JE, Mackey DA. Aetiology of congenital and paediatric cataract in an Australian population. *Br J Ophthalmol* 2002; 86:782-6.
- Vanita, Singh JR, Singh D. Genetic and segregation analysis of congenital cataract in the Indian population. *Clin Genet* 1999; 56:389-93.
- McKusick VA. Mendelian Inheritance in Man. A Catalog of Human Genes and Genetic Disorders. 12th ed. Baltimore (MD): Johns Hopkins University Press; 1998.
- Amaya L, Taylor D, Russell-Eggitt I, Nischal KK, Lengyel D. The morphology and natural history of childhood cataracts. *Surv Ophthalmol* 2003; 48:125-44.
- Jaffe NS, Horwitz J. Lens and cataract. In: Podos SM, Yanoff M, editors. Text book of Ophthalmology. Vol. 3. New York: Gower Medical Publishing; 1992. p. 1.7.
- Kuszak JR, Zoltoski RK, Tiedemann CE. Development of lens sutures. *Int J Dev Biol* 2004; 48:889-902.
- Kuszak JR, Al-Ghoul KJ, Novak LA, Peterson KL, Herbert KL, Sivak JG. The internalization of posterior subcapsular cataracts (PSCs) in Royal College of Surgeons (RCS) rats. II. The interrelationship of optical quality and structure as a function of age. *Mol Vis* 1999; 5:7 .
- Eiberg H, Lund AM, Warburg M, Rosenberg T. Assignment of congenital cataract Volkmann type (CCV) to chromosome 1p36. *Hum Genet* 1995; 96:33-8.
- Conley YP, Erturk D, Keveline A, Mah TS, Keravala A, Barnes LR, Bruchis A, Hess JF, FitzGerald PG, Weeks DE, Ferrell RE, Gorin MB. A juvenile-onset, progressive cataract locus on chromosome 3q21-q22 is associated with a missense mutation in the beaded filament structural protein-2. *Am J Hum Genet* 2000; 66:1426-31.
- Jakobs PM, Hess JF, FitzGerald PG, Kramer P, Weleber RG, Litt M. Autosomal-dominant congenital cataract associated with a deletion mutation in the human beaded filament protein gene BFP2. *Am J Hum Genet* 2000; 66:1432-6.
- Zhang Q, Guo X, Xiao X, Yi J, Jia X, Hejtmanck JF. Clinical description and genome wide linkage study of Y-sutural cataract and myopia in a Chinese family. *Mol Vis* 2004; 10:890-900 .
- Vanita, Singh JR, Sarhadi VK, Singh D, Reis A, Rueschendorf F, Becker-Follmann J, Jung M, Sperling K. A novel form of "central pouchlike" cataract, with sutural opacities, maps to chromosome 15q21-22. *Am J Hum Genet* 2001; 68:509-14.
- Bu L, Jin Y, Shi Y, Chu R, Ban A, Eiberg H, Andres L, Jiang H, Zheng G, Qian M, Cui B, Xia Y, Liu J, Hu L, Zhao G, Hayden MR, Kong X. Mutant DNA-binding domain of HSF4 is associated with autosomal dominant lamellar and Marner cataract. *Nat Genet* 2002; 31:276-8.
- Padma T, Ayyagari R, Murty JS, Basti S, Fletcher T, Rao GN, Kaiser-Kupfer M, Hejtmanck JF. Autosomal dominant zonular cataract with sutural opacities localized to chromosome 17q11-12. *Am J Hum Genet* 1995; 57:840-5.
- Mackay DS, Boskovska OB, Knopf HL, Lampi KJ, Shiels A. A nonsense mutation in CRYBB1 associated with autosomal dominant cataract linked to human chromosome 22q. *Am J Hum Genet* 2002; 71:1216-21.
- Vanita, Sarhadi V, Reis A, Jung M, Singh D, Sperling K, Singh JR, Burger J. A unique form of autosomal dominant cataract explained by gene conversion between beta-crystallin B2 and its pseudogene. *J Med Genet* 2001; 38:392-6.
- Boyadjiev SA, Justice CM, Eyaid W, McKusick VA, Lachman RS, Chowdry AB, Jabak M, Zwaan J, Wilson AF, Jabs EW. A novel dysmorphic syndrome with open calvarial sutures and sutural cataracts maps to chromosome 14q13-q21. *Hum Genet* 2003; 113:1-9.

19. Burdon KP, McKay JD, Sale MM, Russell-Eggitt IM, Mackey DA, Wirth MG, Elder JE, Nicoll A, Clarke MP, FitzGerald LM, Stankovich JM, Shaw MA, Sharma S, Gajovic S, Gruss P, Ross S, Thomas P, Voss AK, Thomas T, Gecz J, Craig JE. Mutations in a novel gene, NHS, cause the pleiotropic effects of Nance-Horan syndrome, including severe congenital cataract, dental anomalies, and mental retardation. *Am J Hum Genet* 2003; 73:1120-30.
20. Girelli D, Corrocher R, Bisceglia L, Olivieri O, De Franceschi L, Zelante L, Gasparini P. Molecular basis for the recently described hereditary hyperferritinemia-cataract syndrome: a mutation in the iron-responsive element of ferritin L-subunit gene (the "Verona mutation"). *Blood* 1995; 86:4050-3.
21. Levi S, Girelli D, Perrone F, Pasti M, Beaumont C, Corrocher R, Albertini A, Arosio P. Analysis of ferritins in lymphoblastoid cell lines and in the lens of subjects with hereditary hyperferritinemia-cataract syndrome. *Blood* 1998; 91:4180-7.
22. Mumford AD, Vulliamy T, Lindsay J, Watson A. Hereditary hyperferritinemia-cataract syndrome: two novel mutations in the L-ferritin iron-responsive element. *Blood* 1998; 91:367-8.
23. Beaumont C, Leneuve P, Devaux I, Scoazec JY, Berthier M, Loiseau MN, Grandchamp B, Bonneau D. Mutation in the iron responsive element of the L ferritin mRNA in a family with dominant hyperferritinaemia and cataract. *Nat Genet* 1995; 11:444-6.
24. Cazzola M, Bergamaschi G, Tonon L, Arbustini E, Grasso M, Vercesi E, Barosi G, Bianchi PE, Cairo G, Arosio P. Hereditary hyperferritinemia-cataract syndrome: relationship between phenotypes and specific mutations in the iron-responsive element of ferritin light-chain mRNA. *Blood* 1997; 90:814-21.
25. Dib C, Faure S, Fizames C, Samson D, Drouot N, Vignal A, Millasseau P, Marc S, Hazan J, Seboun E, Lathrop M, Gyapay G, Morissette J, Weissenbach J. A comprehensive genetic map of the human genome based on 5,264 microsatellites. *Nature* 1996; 380:152-4.
26. Lathrop GM, Lalouel JM. Easy calculations of lod scores and genetic risks on small computers. *Am J Hum Genet* 1984; 36:460-5.
27. Kruglyak L, Daly MJ, Reeve-Daly MP, Lander ES. Parametric and nonparametric linkage analysis: a unified multipoint approach. *Am J Hum Genet* 1996; 58:1347-63.
28. Cicilano M, Zecchina G, Roetto A, Bosio S, Infelise V, Stefani S, Mazza U, Camaschella C. Recurrent mutations in the iron regulatory element of L-ferritin in hereditary hyperferritinemia-cataract syndrome. *Haematologica* 1999; 84:489-92.
29. Leibold EA, Laudano A, Yu Y. Structural requirements of iron-responsive elements for binding of the protein involved in both transferrin receptor and ferritin mRNA post-transcriptional regulation. *Nucleic Acids Res* 1990; 18:1819-24.
30. Jaffrey SR, Haile DJ, Klausner RD, Harford JB. The interaction between the iron-responsive element binding protein and its cognate RNA is highly dependent upon both RNA sequence and structure. *Nucleic Acids Res* 1993; 21:4627-31.
31. Martin ME, Fargion S, Brissot P, Pellat B, Beaumont C. A point mutation in the bulge of the iron-responsive element of the L ferritin gene in two families with the hereditary hyperferritinemia-cataract syndrome. *Blood* 1998; 91:319-23.
32. Allerson CR, Cazzola M, Rouault TA. Clinical severity and thermodynamic effects of iron-responsive element mutations in hereditary hyperferritinemia-cataract syndrome. *J Biol Chem* 1999; 274:26439-47.
33. Balas A, Aviles MJ, Garcia-Sanchez F, Vicario JL. Description of a new mutation in the L-ferritin iron-responsive element associated with hereditary hyperferritinemia-cataract syndrome in a Spanish family. *Blood* 1999; 93:4020-1.
34. Girelli D, Bozzini C, Zecchina G, Tinazzi E, Bosio S, Piperno A, Ramenghi U, Peters J, Levi S, Camaschella C, Corrocher R. Clinical, biochemical and molecular findings in a series of families with hereditary hyperferritinaemia-cataract syndrome. *Br J Haematol* 2001; 115:334-40.
35. Perez de Nanclares G, Castano L, Martul P, Rica I, Vela A, Sanjurjo P, Aldamiz-Echevarria K, Martinez R, Sarrionandia MJ. Molecular analysis of hereditary hyperferritinemia-cataract syndrome in a large Basque family. *J Pediatr Endocrinol Metab* 2001; 14:295-300.
36. Brooks DG, Manova-Todorova K, Farmer J, Lobmayr L, Wilson RB, Eagle RC Jr, St Pierre TG, Stambolian D. Ferritin crystal cataracts in hereditary hyperferritinemia cataract syndrome. *Invest Ophthalmol Vis Sci* 2002; 43:1121-6.
37. Mumford AD, Cree IA, Arnold JD, Hagan MC, Rixon KC, Harding JJ. The lens in hereditary hyperferritinaemia cataract syndrome contains crystalline deposits of L-ferritin. *Br J Ophthalmol* 2000; 84:697-700.
38. Kato GJ, Casella F. L-ferritin-Baltimore-1: a novel mutation in the iron response element (C32G) as a cause of the hyperferritinemia-cataract syndrome [abstract]. *Blood*. 1999; 94:407a.
39. Campagnoli MF, Pimazzoni R, Bosio S, Zecchina G, DeGobbi M, Bosso P, Oldani B, Ramenghi U. Onset of cataract in early infancy associated with a 32G→C transition in the iron responsive element of L-ferritin. *Eur J Pediatr* 2002; 161:499-502.
40. Craig JE, Clark JB, McLeod JL, Kirkland MA, Grant G, Elder JE, Toohey MG, Kowal L, Savoia HF, Chen C, Roberts S, Wirth MG, Mackey DA. Hereditary hyperferritinemia-cataract syndrome: prevalence, lens morphology, spectrum of mutations, and clinical presentations. *Arch Ophthalmol* 2003; 121:1753-61.
41. McLeod JL, Craig J, Gumley S, Roberts S, Kirkland MA. Mutation spectrum in Australian pedigrees with hereditary hyperferritinaemia-cataract syndrome reveals novel and de novo mutations. *Br J Haematol* 2002; 118:1179-82.
42. Hetet G, Devaux I, Soufir N, Grandchamp B, Beaumont C. Molecular analyses of patients with hyperferritinemia and normal serum iron values reveal both L ferritin IRE and 3 new ferroportin (slc11a3) mutations. *Blood* 2003; 102:1904-10.