



University of HUDDERSFIELD

University of Huddersfield Repository

Rahman, Rubina, Oxley, L. and Stephenson, John

Persistent outer retinal fluid following non-posturing surgery for idiopathic macular hole

Original Citation

Rahman, Rubina, Oxley, L. and Stephenson, John (2013) Persistent outer retinal fluid following non-posturing surgery for idiopathic macular hole. *British Journal of Ophthalmology*, 97 (11). pp. 1451-1454. ISSN 0007-1161

This version is available at <http://eprints.hud.ac.uk/id/eprint/18240/>

The University Repository is a digital collection of the research output of the University, available on Open Access. Copyright and Moral Rights for the items on this site are retained by the individual author and/or other copyright owners. Users may access full items free of charge; copies of full text items generally can be reproduced, displayed or performed and given to third parties in any format or medium for personal research or study, educational or not-for-profit purposes without prior permission or charge, provided:

- The authors, title and full bibliographic details is credited in any copy;
- A hyperlink and/or URL is included for the original metadata page; and
- The content is not changed in any way.

For more information, including our policy and submission procedure, please contact the Repository Team at: E.mailbox@hud.ac.uk.

<http://eprints.hud.ac.uk/>

Persistent outer retinal fluid following non-posturing surgery for idiopathic macular hole

Rahman R¹, Oxley L¹, Stephenson J²

KEYWORDS: macular hole, OCT, non-posturing, outer foveal defect.

Addresses:

¹Ms Rubina Rahman* and Dr. Lucy Oxley, Calderdale Royal Hospital, Salterhebble Hill, Halifax, HX3 0NJ United Kingdom. Rubina.Rahman@nhs.net Tel. 01422 222977. Fax. 01422 222544.

² Dr John Stephenson PhD CMath MIMA FRSS, Senior Lecturer in Health and Biomedical Statistics, School of Human and Health Sciences, University of Huddersfield, Queensgate, Huddersfield HD1 3DH, United Kingdom.

*Corresponding author.

WORD COUNT: 2794 words

This work has no proprietary interest or research funding.

Authorship and contributorship:

1. R Rahman: Conception and design of study, acquisition and analysis of data, revising the article critically and approval of the version to be published.
2. L Oxley: Collection and analysis of data, drafting and revising the article. Approval of the published version.
3. J Stephenson: Statistical analysis of the data, revising the article and final approval of the published version.

Abstract:

Purpose: To present the anatomical and visual outcomes of patients with hypo reflective cystic defects in outer fovea (OFD) in macular holes repaired with non-posturing vitrectomy and short term gas tamponade. To identify the incidence and risk factors for developing OFD foveal defect

Method: A prospective consecutive case series of 58 patients, undergoing macular hole surgery was undertaken. Any OFD on their two week post-operative OCT was measured, and in these patients OCT was performed monthly until resolution of OFD was observed.

Results: 27 eyes (46.6%) had an outer defect at 2 weeks, the presence of which was significantly associated with macular holes with larger base diameters preoperatively ($p=0.006$). All defects closed spontaneously without further intervention, and the final vision was not affected by the presence of an OFD. Visual recovery was only slightly (and not significantly) delayed by the presence of an outer defect.

Conclusions: This is the first study of outcomes of OFDs following macular hole surgery in patients who did not posture postoperatively. OFDs are common but do not adversely affect visual outcomes.

Introduction:

Macular hole repair with vitrectomy and peeling of internal limiting membrane (ILM) is reported to achieve successful hole closure in 90-98% of cases¹⁻³. Clinical hole closure may be different to anatomical hole closure, especially in the era of increasingly higher definition imaging of the retinal architecture. Optical Coherence Tomography (OCT) has evolved from time domain to spectral domain providing as little as 5 microns of axial resolution of retinal anatomy, thus improving the visualisation of hole architecture. This has led researchers to demonstrate 5 different retinal abnormalities after flat closed macular holes⁴. These include outer foveal hypo-reflective defects, persistent foveal detachment, moderately reflective foveal lesions, epiretinal membranes (ERM) and nerve fibre layer defects (NFL).

An outer foveal defect (OFD) following macular hole surgery is one in which the hole clinically appears closed. However, on OCT evaluation, there is a hypo-reflective cystic space in the outer fovea representing persistent outer retinal fluid. The incidence is reported to range from 34% to 49% in previous reports⁵⁻⁸ in relation to posturing macular hole surgery. We aim to determine whether lack of posturing post macular hole surgery influences the incidence and visual recovery as well as final vision in these patients.

Methods:

A prospective consecutive case series of 58 eyes from 58 patients undergoing surgery for idiopathic macular hole was performed. Cases were operated by one surgeon (RR) between May 2009 and November 2011. Only patients in whom the macular hole was closed post-operatively were included.

Preoperative data included age, gender and best-corrected visual acuity (BCVA). BCVA refers to pinhole vision, apart from the final vision which was recorded with new distance prescription. All patients underwent OCT evaluation of macular hole base diameter (BD) and minimal linear diameter (MLD). OCT scanning was performed using spectral domain SD-OCT (Optovue RTVue-100 with Version 4.0 software, Fremont, CA, USA). Twelve radial 6mm OCT images (MM6/Radial slice 0.27 sec) through the centre of the macular hole were obtained by skilled operators.

All patients underwent 23-gauge transconjunctival pars plana vitrectomy, internal limiting membrane peel with Brilliant Peel (Fluoron, Geuder Germany) and endotamponade with sulphur hexafluoride (20% SF₆). Drainage of fluid through the macular hole was not attempted in any of the study patients. Fifty two patients were phakic and underwent combined microincision coaxial phacoemulsification with intraocular lens implant at the time of vitrectomy. The remaining six patients were pseudophakic on presentation after surgery. Patients were not given any positioning instructions.

As SF₆ had completely resolved in 2 weeks, visual acuity and OCT scans were taken at 2 weeks post-operatively, and the maximum horizontal diameter of any outer foveal defect was measured using callipers on OCT. Patients noted to have an outer foveal defect at two weeks, underwent serial monthly OCT scanning measuring the maximum horizontal diameter of the OFD until complete resolution of the was observed. The pre-operative and post-operative BCVA was measured using a standard Snellen acuity, and converted to LogMAR scores for the purposes of statistical analysis. Patients were followed up for a minimum of 3 months or until their best corrected vision was stable on 2 consecutive visits.

Statistical analyses using SPSS software (Version 18.0) were undertaken on a data set of 58 patients, of which 27 developed an OFD and 31 did not. Patients were discharged after resolution of the outer retinal fluid and improvement/stabilisation of vision on two consecutive visits.

A logistic regression analysis was undertaken to assess the effect of macular hole base diameter, minimum linear diameter (MLD) and demographic factors on risk of developing a foveal defect. Due to the limited numbers of patients with co-morbidities/complications of any kind, this data was discretised to compare those with and without either age-related macular degeneration (AMD) or retinal detachment, without distinguishing between these conditions.

A Kaplan-Meier non-parametric time-to-event analysis was performed on the data to compare times to recovery of vision in patients with and without an OFD, with comparisons facilitated both graphically and using the log-rank statistic.

An analysis of covariance (ANCOVA)-type regression analysis was also undertaken to investigate the effect of various factors and covariates on change in vision following surgery, assessed using the linear LogMAR scale. In addition to the baseline vision level, variables considered included macular hole base diameter, MLD, age, co-morbidities/complications (defined as in the logistic regression analysis outlined above) and the size of any outer foveal defect if present. The extent of the correlation between baseline vision and macular hole base diameter was also assessed.

Results:

The 58 patients comprised 37 females (63.8%) and 21 males (36.2%) spanning an age range of 47 to 86 years (mean 70.4 years).

Effect of macular hole base diameter and demographic factors on risk of developing defect

A total of 27 patients (46.6%) had developed an OFD; of which 17 were females and 10 were males. OFDs observed ranged in size up to 754µm (mean 309µm) after 2 weeks and 829µm (mean 205µm) after 6 weeks.

The means and standard deviation of age, pre-operative base diameters (BD)and, mean linear diameter (MLD) of macular holes are shown in table 1.

Table 1: summary of key descriptive statistics

	All patients (n=58)	With OFD (n=27)	Without OFD (n=31)
Macular hole base diameter (µm)			
Mean (SD)	610 (235)	667 (173)	561 (271)
Range	95 – 1370	329 – 944	95 – 1370
Age (years)			
Mean (SD)	70.4 (8.79)	69.3 (9.32)	71.5 (8.32)
Range	47.0 – 86.0	47.0 – 86.0	50.0 – 85.0
Mean linear diameter (µm)			
Mean (SD)	351 (124)	353 (114)	350 (134)
Range	146 – 722	146 – 722	177 – 690

38 patients (65.5%) had MLD values of 400µm or below. Amongst patients with lower MLD values, 18 (47.4%) had an OFD. Amongst patients with higher MLD values, 9 (45.0%) had an OFD. The association between MLD values (dichotomised as above) and OFD formation was non-significant ($p=0.864$).

The logistic regression analysis found base diameter, MLD and age to be significantly associated with the probability of OFD ($p=0.006$ for base diameter; $p=0.043$ for MLD; $p=0.032$ for age); with increased odds of OFD development in patients with larger MH base diameters and with smaller MLD measurements, and in younger patients. Co-morbidities/complications was not found to be significantly associated with the probability of defect formation ($p=0.362$). Post-operative complications included one case of post-operative inferior rhegmatogenous retinal detachment with PVR (proliferative vitreo-retinopathy) and 3 cases of posterior capsular opacification.

Table 2: p-values, odds ratios and associated confidence intervals for factors/covariates potentially influencing development of foveal defect

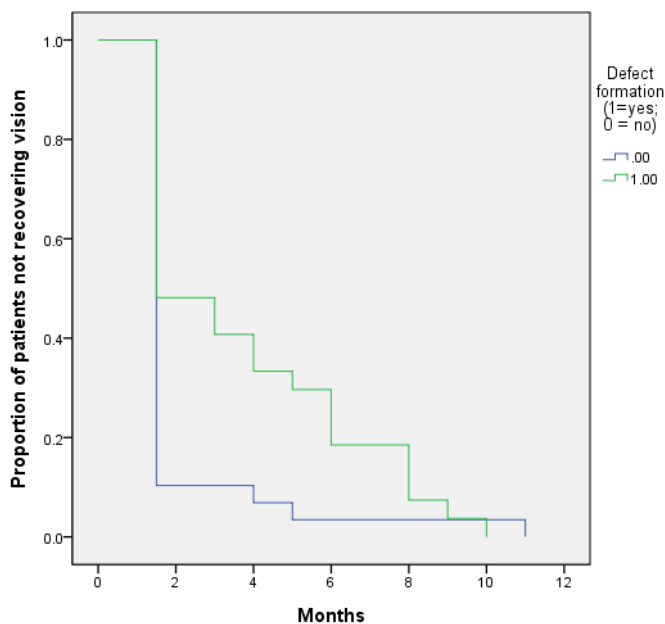
Variable	p-value	Odds ratio	95% CI for OR
Macular hole base diameter (µm)	0.006	1.006	(1.002, 1.010)
Mean linear diameter (µm)	0.043	0.992	(0.985, 1.000)
Age (years)	0.032	0.919	(0.850, 0.993)
Co-morbidities/complications			
No co-morbidities/complications (reference)			
Co-morbidities/complications	0.362	0.428	(0.069, 2.652)

Effect of developing defect on time to recovery of vision:

All patients recovered vision by 11 months, with mean time to recovery 2.98 months. Mean time for vision recovery ranged from 1.5 to 10 months (mean 3.74 months) amongst patients who experienced OFD formation. Mean time for vision recovery ranged from 1.5 to 11 months (mean 2.03 months) amongst those patients who did not experience OFD formation. Hence mean time to vision recovery was greater in patients who experienced OFD formation. This difference in vision recovery experience was of near-borderline significance ($\chi^2_{(1)}=3.72$; $p=0.054$) using the log-rank statistic derived from the Kaplan-Meier analysis.

Figure 1 below illustrates distinct experience of vision recovery in the “with defect” and “without defect” groups; indicative of a substantive difference between the two groups, with the proportion of patients with recovered vision being as great or greater amongst patients with no OFD than in patients with an OFD at all times up to 11 months. Despite the generally more rapid improvements in vision seen in patients without OFD, vision in all patients with OFDs was recovered one month earlier (at 10 months) than in patients without OFDs, all of whom had recovered vision by 11 months.

Figure 1: Times to vision recovery in patients with and without foveal defects



Neither the comorbidities/complications category nor any of the other covariates were significantly associated with time to visual recovery. *P*-values, odds ratios and associated confidence intervals for analysis of time to vision recovery are summarised in Table 3.

Table 3: p-values, odds ratios and associated confidence intervals for analysis of time to vision recovery in patients: Cox model

Variable	<i>p</i> -value	Hazard ratio	95% CI for hazard ratio
Macular hole base diameter (µm)	0.313	0.999	(0.997, 1.001)
Mean linear diameter (µm)	0.435	1.001	(0.998, 1.005)
Age (years)	0.233	1.023	(0.985, 1.063)
Foveal defect size after 26 weeks	0.649	0.626	(0.083, 4.695)
Presence of co-morbidities or complications			
No co-morbidities or complications (reference)			
Co-morbidities or complications	0.115	0.478	(0.190, 1.198)

Effect of ophthalmic and demographic factors on extent of recovered vision

The final vision on the LogMAR scale ranged from 0.00 to 1.00, with a mean score of 0.30. Change in vision from preoperative readings on the LogMAR scale ranged from a deterioration of 0.40 to an improvement of 1.38, with a mean improvement of 0.47. Patients with and without OFDs showed almost identical mean improvements in vision.

The ANCOVA model found baseline vision to be significantly associated with the final recovered vision ($p=0.001$), controlling for other variables. Other demographic and ophthalmic parameters were not found to be significantly associated with the final recovered vision. No excessive correlations between predictor variables were observed.

Unstandardised and standardised coefficients of all parameters considered, *p*-values and associated confidence intervals are given in Table 4 below. In this analysis, macular hole base diameter, minimum linear diameter and outer foveal defect size are measured in mm.

Table 4: Regression coefficients, p-values and associated 95% confidence intervals for analysis of extent of improved vision in patients

Covariate	Unstandardised coefficients		Standardised coefficients	p-value	95% CI for β
	β	SE(β)			
Constant	-0.201	0.213	-	-	-
Pre-operative LogMAR score	0.304	0.093	0.446	0.002	(0.117, 0.491)
Age (years)	0.003	0.003	0.147	0.283	(-0.003, 0.009)
Macular hole base diameter (mm)	-0.097	0.148	-0.121	0.516	(-0.192, 0.231)
Foveal defect size after 26 weeks (mm)	-0.093	0.156	-0.073	0.555	(-0.394, 0.200)
Mean linear diameter (mm)	0.312	0.279	0.206	0.269	(-0.248, 0.873)
Co-morbidities/complications					
No co-morbidities/complications (reference)					
Co-morbidities/complications	0.045	0.068	0.083	0.511	(-0.091, 0.180)

Discussion:

Previously it has been shown that excellent success rates can be achieved with non-posturing macular hole surgery using shorter acting gas³. Rapid absorption of the gas bubble allows quicker visual rehabilitation. However, whether or not the combination of shorter acting gas and non-posturing surgery increase the risk of developing outer defects after macular hole surgery remains to be determined. This study of 58 patients with non-posturing surgery for idiopathic macular hole treated with vitrectomy, ILM peel and SF₆ gas, found the incidence of outer foveal defect on OCT at two weeks to be 46.6%.

The incidence is comparable to other studies in which patients postured for 5-10 days post macular hole surgery.⁴⁻⁶ Kawano et al⁴ report an incidence of 49% at one month following combined phaco-vitrectomy and SF₆ gas. The incidence in the study of Kang et al. was 45.8%⁶. The only risk factor for developing an outer foveal defect in our study was the preoperative base diameter of macular hole, with larger holes more likely to have an outer defect at two weeks ($p=0.006$). Although the incidence of OFD was slightly higher in macular holes with MLD <400 μ m then those with MLD >400 μ m, the association was non-significant ($p=0.043$). No other factors (age, sex or co-morbidities such as AMD) had a bearing on the presence of an outer defect. In contrast to our results, two earlier studies have shown that outer defects are more likely to occur in patients who have smaller diameter macular hole preoperatively.^{5,6} It was postulated by Kang et al. that this is because of the way in which glial cells commence proliferation in the healing process of the macular hole⁶. No other theories have been put forward. The foveal defects did all gradually shrink and resolve over time, in agreement with previous studies^{5,6}. Our study is the first to measure the outer defects using SD-OCT; however, the size of defect measured after 6 weeks was not found to be associated with final vision (Table 4) controlling for other variables. It may also be shown that defect size after 6 weeks did not correlate with preoperative base diameter.

The final vision was no different in patients who had a defect compared to those without. Final vision ranged from 1.0 to 0.0 with a mean of 0.3 LogMAR. The mean improvement of 0.47 was almost identical in both groups. Kawano and Mason also report no effect of a defect on the final visual outcome, achieving mean visions of 0.13 and 0.426 respectively^{5,7}. Kang actually found that their visual outcomes were better in the group who had a foveal defect, but the authors acknowledge that the difference in preoperative size of macular hole may explain this⁶. The only factor found to influence final vision in our study was the preoperative level of vision.

Visual recovery was taken as the time to reach final visual acuity, and in all cases this occurred by 11 months. The presence of a defect did not significantly delay visual recovery in this sample ($p=0.054$), although there was only one patient in the without-defect group who took longer than 5 months for vision to stabilise (11 months). Without this patient (who had AMD), the difference would have been statistically significant. Including this patient in the statistical analysis, the mean time for vision to stabilise was 2.03 months in the without-defect group, and 3.74 months in the with-defect group, and it can be seen in the figure that the trend was for a more rapid recovery in patients without a defect. Previous studies have not commented on the time taken for visual recovery, so there is no corroborating evidence. However, it follows that a defect in the photoreceptor layer which is gradually shrinking to reach resolution is likely to delay the recovery of vision.

In summary, outer foveal defects are fairly common after macular hole surgery and do not adversely affect the final visual outcome. We found that they were more likely in patients with larger pre-operative macular holes, in contrast to other studies. The key difference between our study and previous ones is the lack of posturing. Non-posturing surgery has similar outcomes to posturing surgery, and there is no difference in the incidence of outer defects nor in the final vision when patients do not posture. The presence of an outer foveal defect did not influence the final vision, only preoperative vision affected this. Finally, the presence of a defect has a borderline but not significant effect on the time taken for visual recovery, although larger studies would help to determine this effect.

References:

1. Almeida DRP, Wong J, Belliveau M et al. Anatomical and visual outcomes of macular hole surgery with short-duration 3-day face-down positioning. *Retina* 2012; 32(3):506-510.
2. Sanisoglu H, Sevim MS, Aktas B et al. Outcomes of 23-gauge pars planavitrectomy and internal limiting membrane peeling with brilliant blue in macular hole. *ClinOphthalmol*. 2011; 5:1177–1183.
3. Rahman R, Madgula I, Khan K. Outcomes of sulfur hexafluoride (SF₆) versus perfluoroethane (C₂F₆) gas tamponade for non-posturing macular-hole surgery. *Br J Ophthalmol* 2012; 96:185-188.
4. Ko TH, Witkin AJ, Fujimoto JG et al. Ultrahigh-resolution optical coherence tomography of surgically closed macular holes. *Arch Ophthalmol* 2006;124(6):827-836.

5. Kawano H, Uemura A, Sakamoto T. Incidence of outer foveal defect after macular hole surgery. *Am J Ophthalmol.*2011;151(2):318-22.
6. Kang SW, Lim JW, Chung SE et al. Outer foveolar defect after surgery for idiopathic macular hole. *Am J Ophthalmol.*2010;150(4):551-7.
7. Moshfeghi A A, Flynn HW, Elner SG. Persistent outer retinal defect *Am J Ophthalmol* 2005;139:1893-184.
8. Sear KS, Bholra RM, Winder S. Visually significant persistent outer retinal fluid following closure of a macular hole. *Acta Ophthalmol. Scand.*2007:85213-215.

Figure 1: Times to vision recovery in patients with and without foveal defects

Figure 2: Outer retinal fluid defect after sealing of sensory retinal closure 2 weeks after macular hole repair.