



# University of HUDDERSFIELD

## University of Huddersfield Repository

Merchant, Hamid A., McConnell, Emma L, Liu, Fang, Ramaswamy, Chandrasekaran, Kulkarni, Rucha P, Basit, Abdul W and Murdan, Sudaxshina

Assessment of gastrointestinal pH, fluid and lymphoid tissue in the guinea pig, rabbit and pig, and implications for their use in drug development.

### Original Citation

Merchant, Hamid A., McConnell, Emma L, Liu, Fang, Ramaswamy, Chandrasekaran, Kulkarni, Rucha P, Basit, Abdul W and Murdan, Sudaxshina (2011) Assessment of gastrointestinal pH, fluid and lymphoid tissue in the guinea pig, rabbit and pig, and implications for their use in drug development. *European Journal of Pharmaceutical Sciences*, 42 (1-2). pp. 3-10. ISSN 0928-0987

This version is available at <http://eprints.hud.ac.uk/id/eprint/19636/>

The University Repository is a digital collection of the research output of the University, available on Open Access. Copyright and Moral Rights for the items on this site are retained by the individual author and/or other copyright owners. Users may access full items free of charge; copies of full text items generally can be reproduced, displayed or performed and given to third parties in any format or medium for personal research or study, educational or not-for-profit purposes without prior permission or charge, provided:

- The authors, title and full bibliographic details is credited in any copy;
- A hyperlink and/or URL is included for the original metadata page; and
- The content is not changed in any way.

For more information, including our policy and submission procedure, please contact the Repository Team at: [E.mailbox@hud.ac.uk](mailto:E.mailbox@hud.ac.uk).

<http://eprints.hud.ac.uk/>

## **Assessment of gastrointestinal pH, fluid and lymphoid tissue in the guinea pig, rabbit and pig, and implications for their use in drug development**

Hamid A. Merchant, Emma L. McConnell, Fang Liu, Chandrasekaran Ramaswamy, Rucha Kulkarni, Abdul W. Basit, and Sudaxshina Murdan\*

Department of Pharmaceutics, The School of Pharmacy, University of London, 29/39 Brunswick Square, London, WC1N 1AX

\* Corresponding author

Email: s.murdan@ucl.ac.uk

Tel: +44 207 753 5810

Fax: +44 207 753 5942

### **Abstract**

Laboratory animals are often used in drug delivery and research. However, basic information about their gastrointestinal pH, fluid volume, and lymphoid tissue is not completely known. We have investigated these in, *post-mortem*, healthy guinea pigs, rabbits, and the pigs to assess their suitability for pre-clinical studies by comparing the results with reported human literature. The mean gastric pH (fed *ad libitum*) was 3.1 and 4.4 in guinea pig and pig respectively. In contrast, a very low pH (1.5) was recorded in the fed rabbits. The small intestinal pH was found in the range of 6.4 to 7.4 in the guinea pigs and rabbits, whereas lower pH (6.1-6.7) was recorded in the pig, which may have consequences for ionisable or pH responsive systems when tested in pig. A relatively lower pH than in the small intestine was found in the caecum (6.0-6.4) and colon (6.1-6.6) of the guinea pig, rabbit and the pig. The water content in the gastrointestinal tract of guinea pig, rabbit and pig was 51 g, 153 g and 1,546 g respectively. When normalized to the body weight, the guinea pig, rabbit and pig had larger amounts of water compared to man (guinea pig > rabbit > pig > man); in contrast, a reverse order was found when normalized to per unit length of the gut (guinea pig < rabbit < pig < man). The lymphoid tissue distribution (lymphoid follicles, Peyer's patches and long strips) along the length of the gut in these animals is presented; in particular, an abundance of lymphoid tissue was found in pig's stomach, small intestine and caecum, and rabbit's appendix. Their ample presence indicated the potential utility of these animal species in oral and colonic vaccination. These differences in the gastrointestinal parameters of the guinea pig, rabbit and pig in comparison to man reiterates the crucial importance of correctly selecting animal models for pre-clinical studies.

### **Keywords**

Gastrointestinal tract, physiology, anatomy, pH, fluid volumes, water content, lymphoid follicles, Peyer's patches, gut associated lymphoid tissue (GALT), colonic vaccination, pre-clinical studies, rabbit, guinea pig, pig

**Table 1.** Gastrointestinal parameters of male guinea pig, rabbit and pig: SDs in small parentheses (n=6 for each species)

Description		Guinea pig	Rabbit	Pig
	Body Weight (Kg)	0.49 (0.03)	2.2 (0.1)	95-110
	Age (weeks)	6-7	9-10	25
Length (cm)	Stomach	5 (1)	8 (0.8)	22.5 (3)
	Stomach, greater curvature	13 (1.3)	21 (3)	63 (6)
	Stomach, lesser curvature	3 (0.5)	4 (0.8)	18 (2)
	Small intestine	148 (5)	267 (39)	1,973 (448)
	Caecum	15 (2)	39 (2)	23 (5)
	Appendix	‡	10 (0.6)	‡
	Colon	100 (7)	109 (3)	413 (47)
	Total GI tract	268 (12)	433 (42)	2,418 (457)
	Total gut length (cm) per kg body weight	545	193	24
	Distance from beginning of the colon after which, faecal beads are seen	28 (2)	33 (6)	†
Area (cm <sup>2</sup> )	Stomach	24 (8)	83 (9)	354 (51)
	Small intestinal	166 (15)	412 (62)	10,492 (3,661)
	* <i>Sacculus rotundus</i>	*	10 (1)	*
	Caecum	100 (26)	362 (51)	3,665 (1,815)
	Appendix	‡	60 (5)	‡
	Colon	124 (17)	200 (13)	35,40 (776)

\* *Sacculus rotundus* (the ileocaecal junction) only found in rabbit

† Faecal beads not seen in pigs

‡ No appendix found in guinea pig and pig

**Table 2.** Distribution of [A] Peyer's patches and [B] lymphoid follicles in guinea pig, rabbit and pig (SD in parenthesis)

[A]

Site	Number of Peyer's patches			Covered area of Peyer's patches (cm <sup>2</sup> )			Number of Peyer's patches /cm <sup>2</sup>		
	Guinea pig	Rabbit	Pig	Guinea pig	Rabbit	Pig	Guinea pig	Rabbit	Pig
Stomach	Nil	Nil	1125 (526) <sup>a</sup>	Nil	Nil	45 (21) <sup>b</sup>	Nil	Nil	3(1) <sup>a</sup>
Small Intestine	11 (3)	7 (4)	†	3.0 (0.6)	7.4 (0.9)	512 (51)	0.1 (0.02)	0.02 (0.01)	†
Caecum	14 (8)	Nil	‡	0.3 (0.2)	Nil	475 (211) ‡	0.2 (0.1)	Nil	‡
Colon	35 (7)	†	584 (218)	0.3 (0.2)	66 (28)	23 (9) <sup>b</sup>	0.2 (0.04)	†	0.19 (0.06)
Total GI tract	61 (10)	7 (4)	1721 (710)	3.5 (0.8)	144 (26)	1250 (144)	0.2 (0.02)	0.01 (0.004)	0.14 (0.06)

† Lymphoid follicles were present as strips

‡ Fully covered with lymphoid follicles

<sup>a</sup> Estimated value considering one Peyer's patch contains five lymphoid follicles

<sup>b</sup> Estimated value considering one Peyer's patch is 0.2cm x 0.2cm

[B]

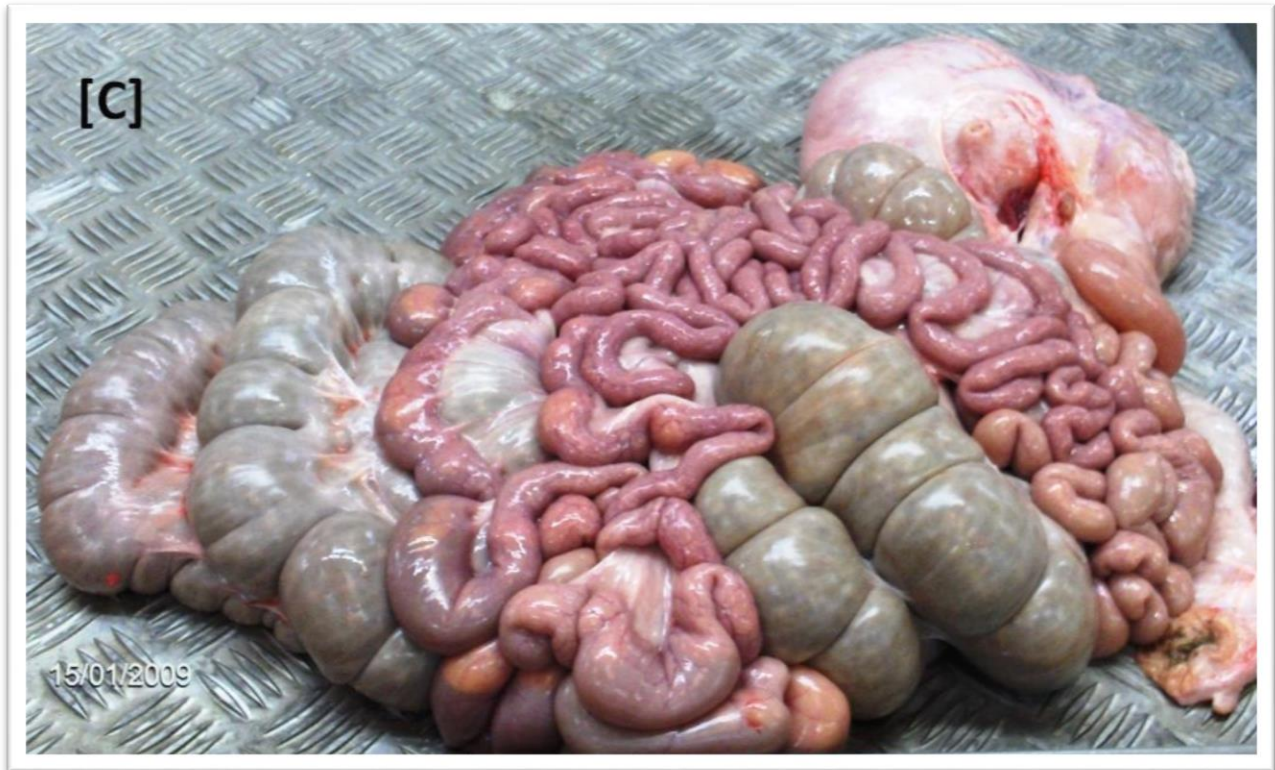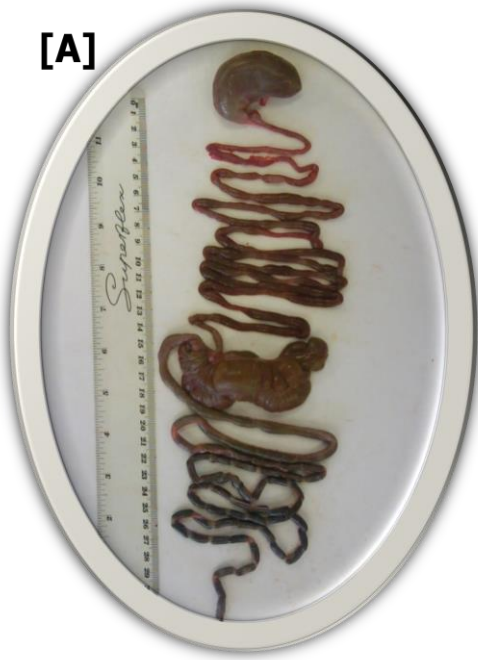Site	Total number of lymphoid follicles (LF)			Number of lymphoid follicles/cm <sup>2</sup>		
	GUINEA PIG	RABBIT	PIG	GUINEA PIG	RABBIT	PIG
Stomach	Nil	Nil	5623 (2632)	Nil	Nil	16 (7)
Small Intestine	190 (55)	450 (87)	51359 (32852)	1.1 (0.3)	1.1 (0.3)	4.6 (1.6)
* <i>Sacculus rotundus</i>	–	1184 (284)	–	–	116 (21)	–
Caecum	165 (143)	Nil	1799 (875)	2.0 (2.1)	Nil	9.6 (7.4)
Appendix	‡	7884 (1351)	‡	‡	130 (14)	‡
Colon	358 (105)	†	23257 (16231)	2.9 (0.9)	†	5.9 (4.3)
Total GI tract	714 (232)	9520 (1490)	71499 (22976)	1.9 (0.7)	9.1 (1.4)	6 (2)

\* Ileocaecal junction in rabbit

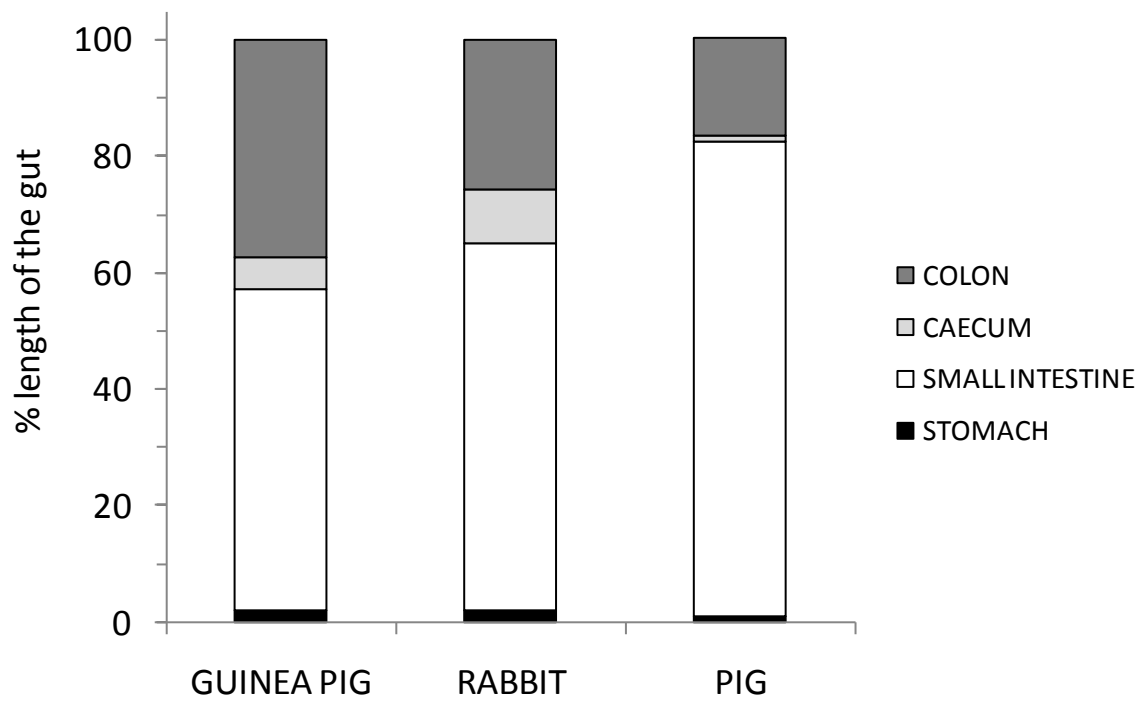
– Not found in the guinea pig and the pig

† Strip of lymphoid follicles (28 ± 11 cm long and 2 ± 0.4cm wide), numbers could not be estimated due to very small size of lymphoid follicles

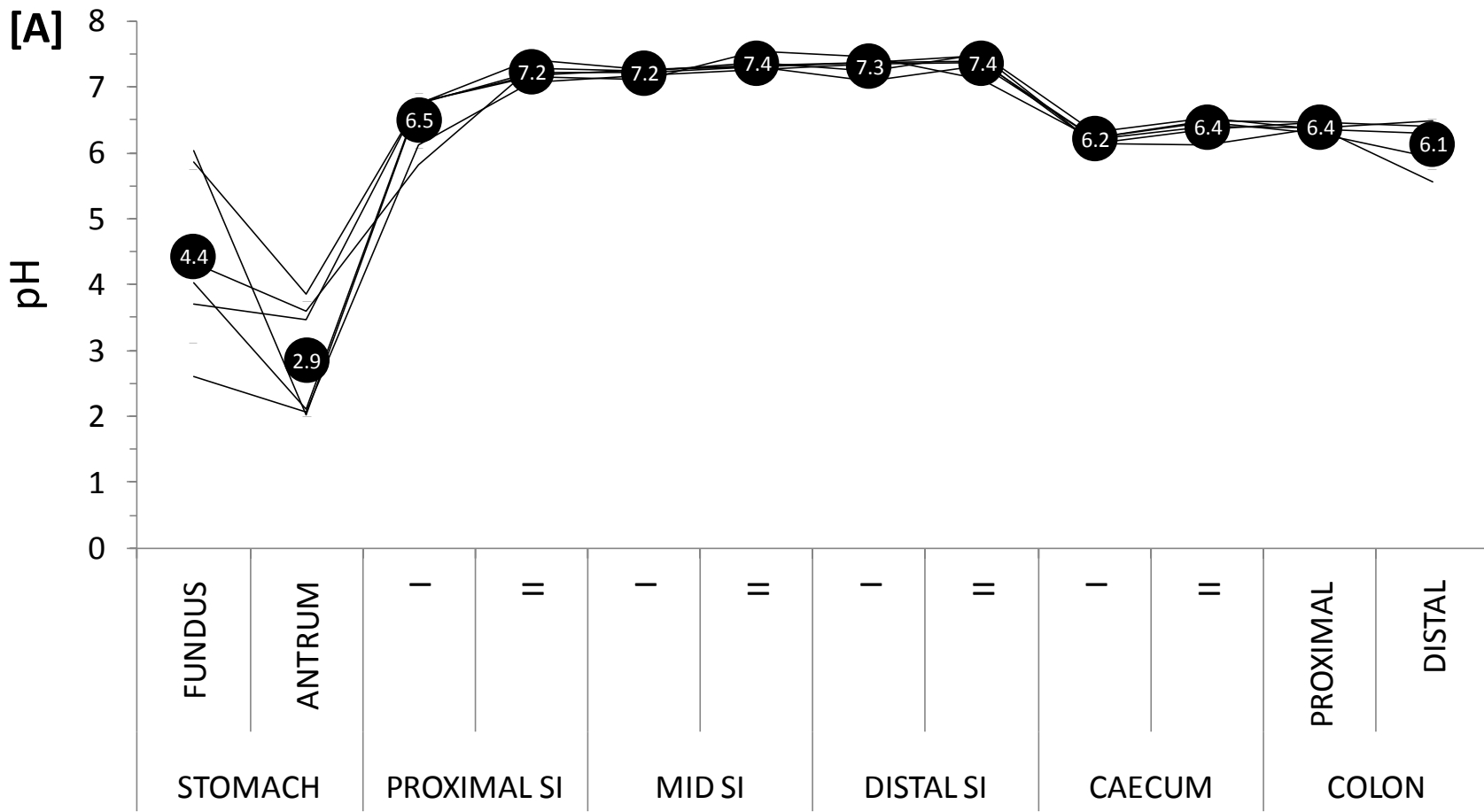
‡ No appendix found in guinea pig and pig



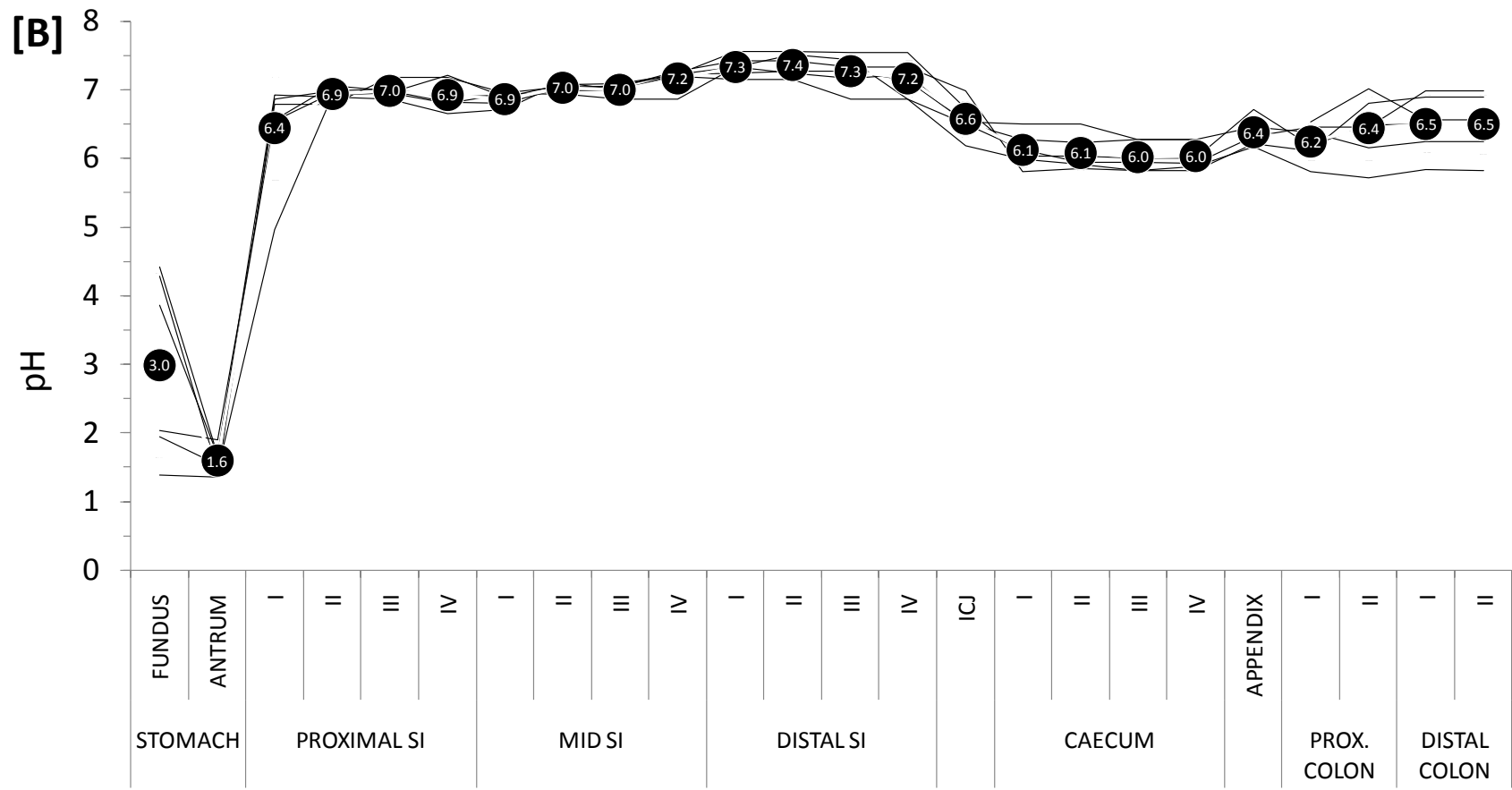
**Figure 1.** Gastrointestinal tract of [A] guinea pig, [B] rabbit, and [C] pig.

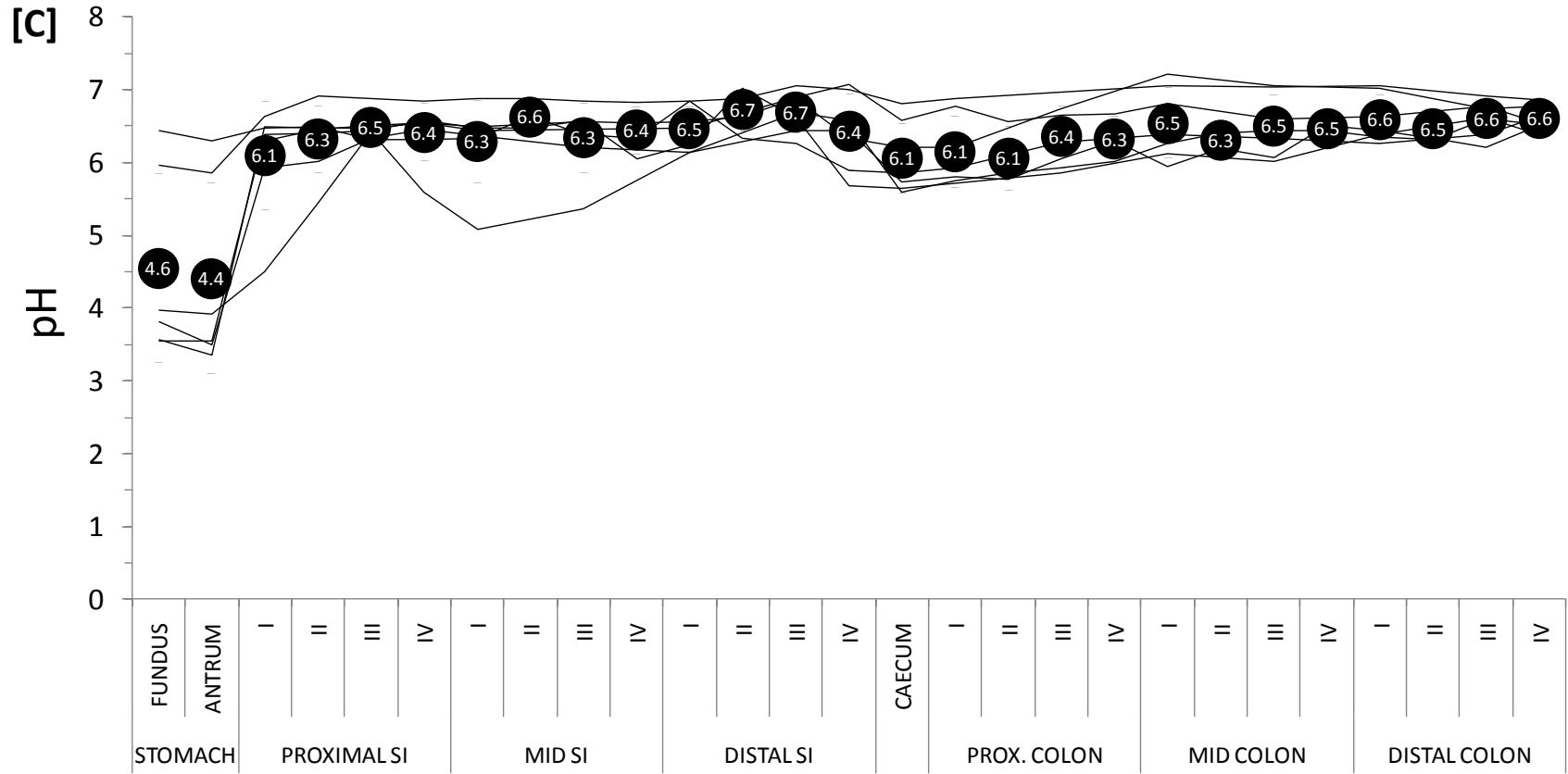


**Figure 2.** Proportion of the total gastrointestinal length represented by stomach, small intestine, caecum and the colon in the guinea pig, rabbit and the pig.

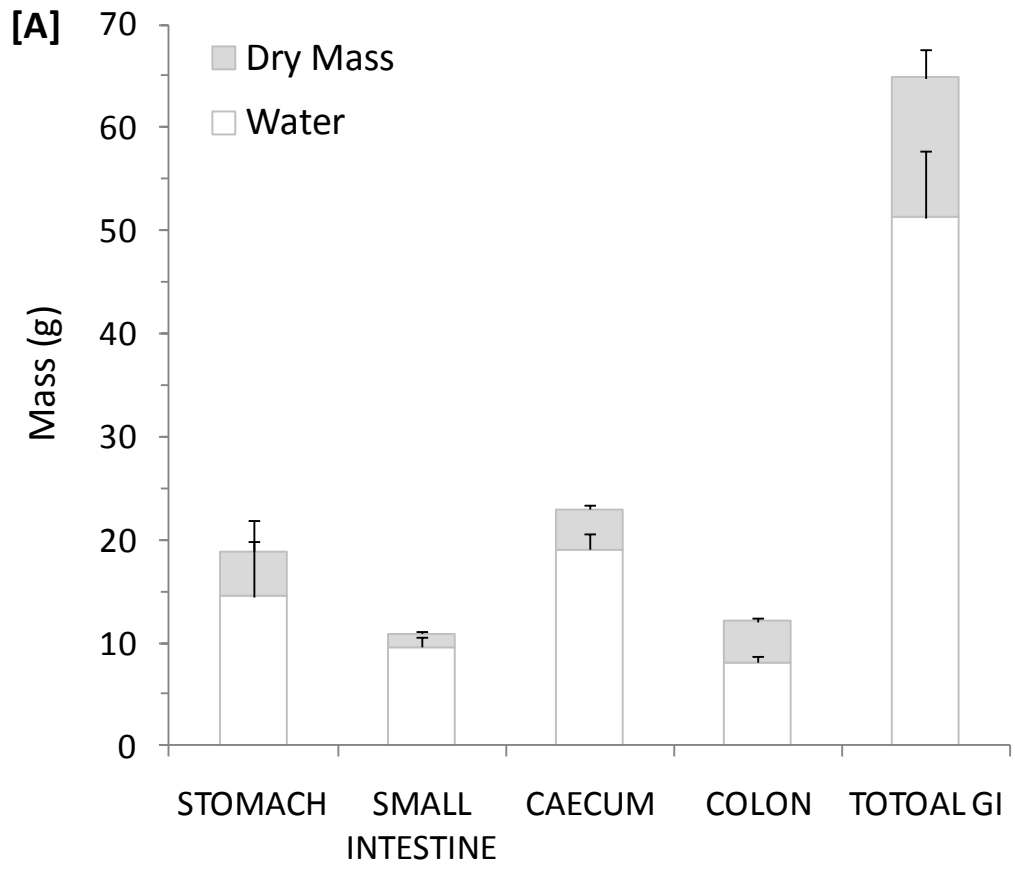


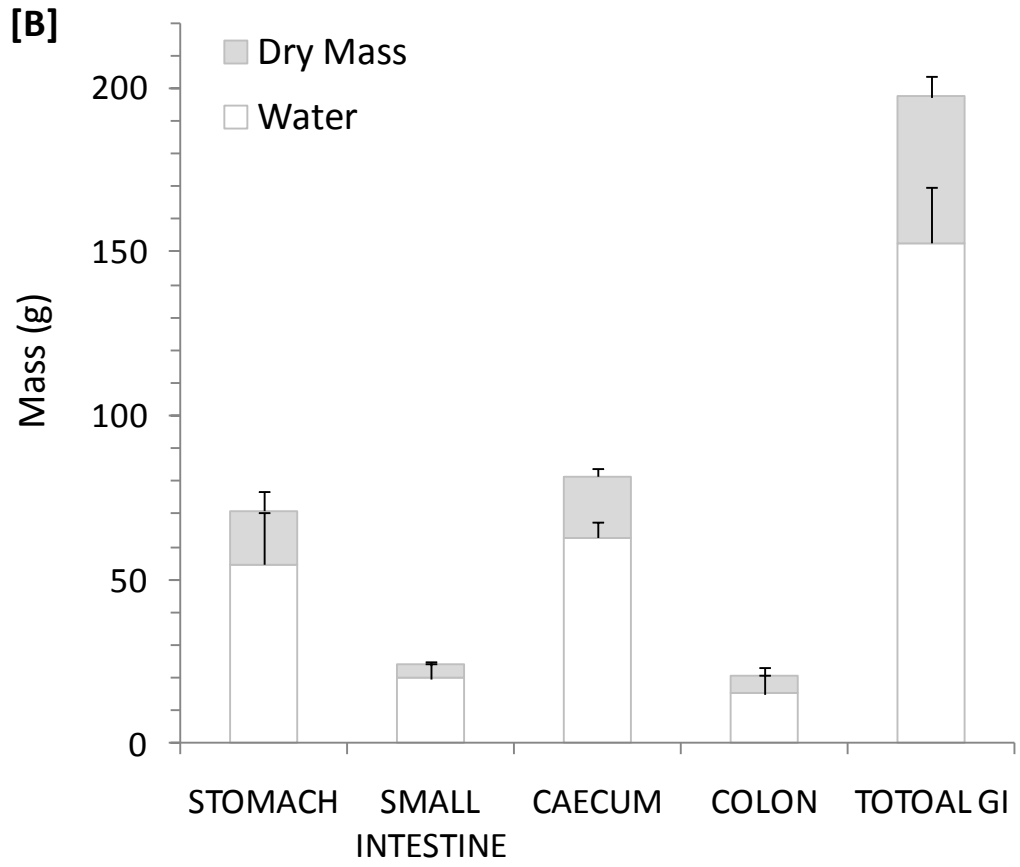


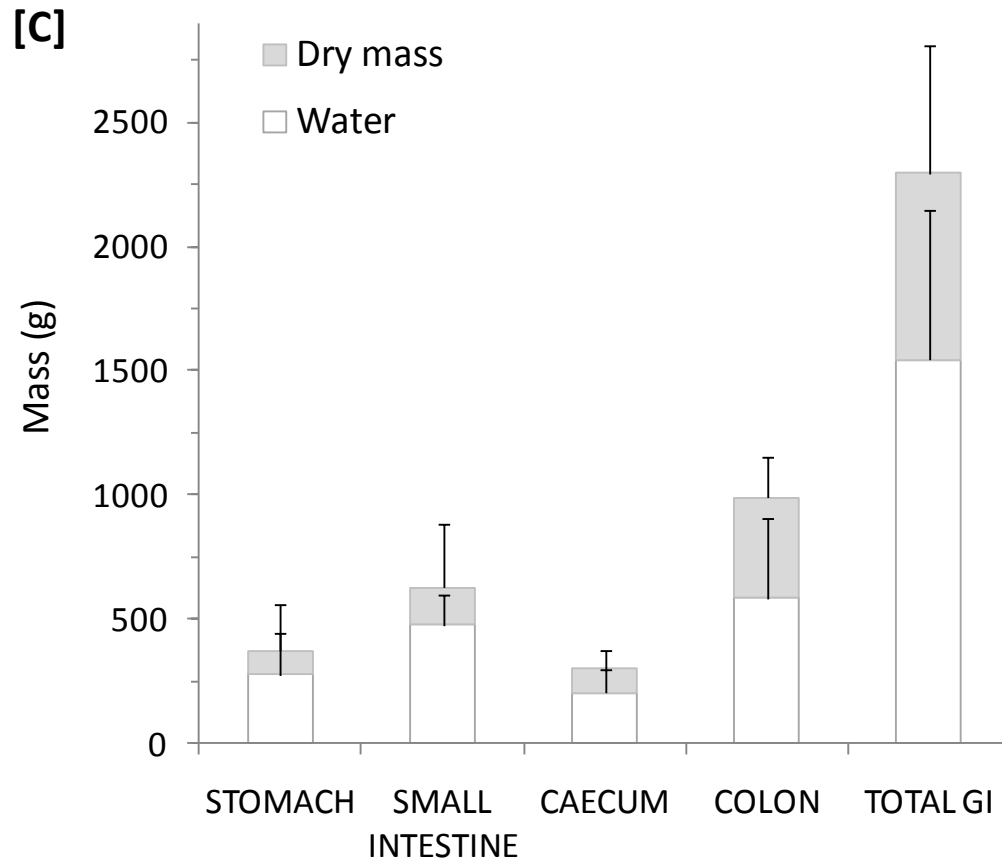




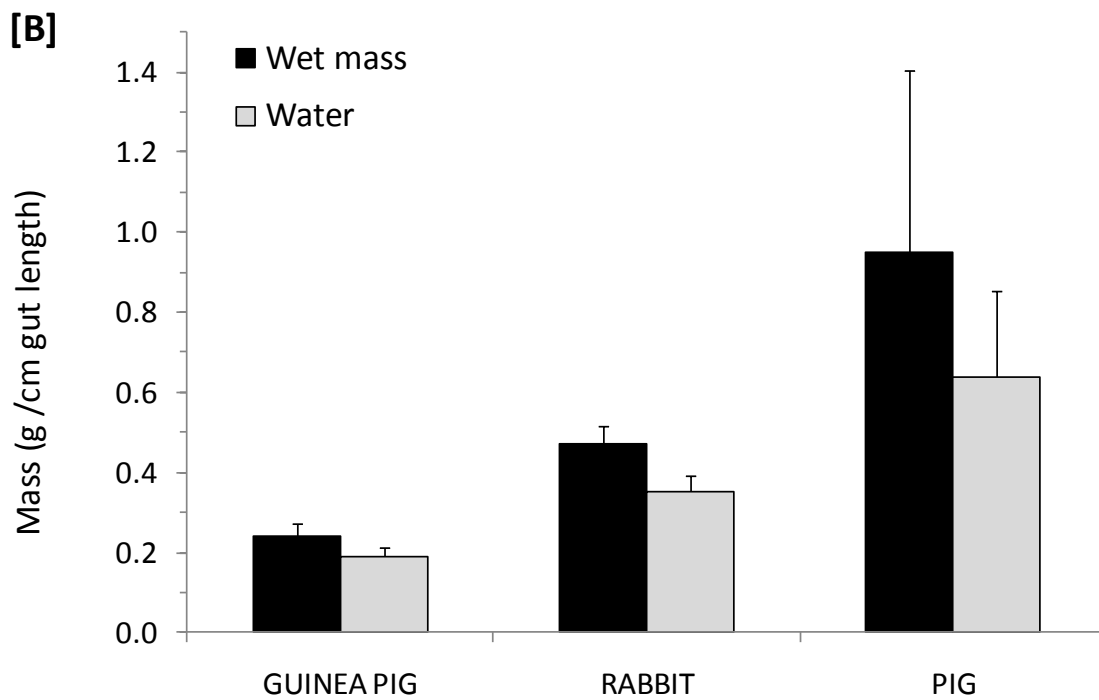
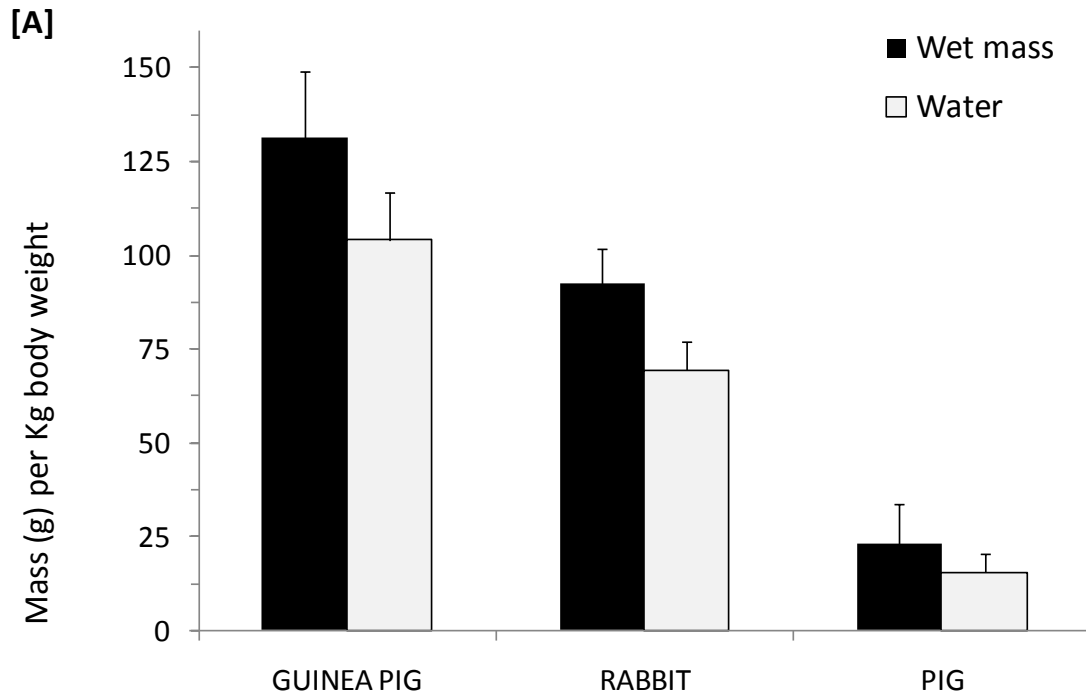
**Figure 3.** Gastrointestinal pH (in-situ) profile under fed (*ad libitum*) state for six healthy male animals [A] guinea pigs, [B] rabbits, [C] pigs (mean pH is shown in filled circles, each line represents one animal)



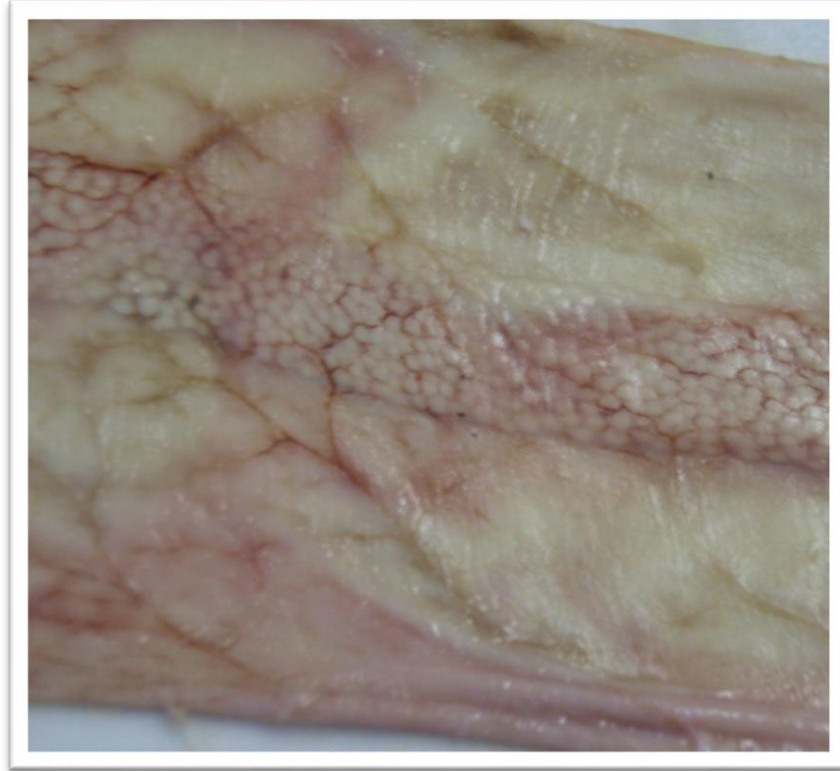




**Figure 4.** Water and solid mass in gastrointestinal tract of six male healthy [A] guinea pigs, [B] rabbits, [C] pigs; (fed, *ad libitum*)



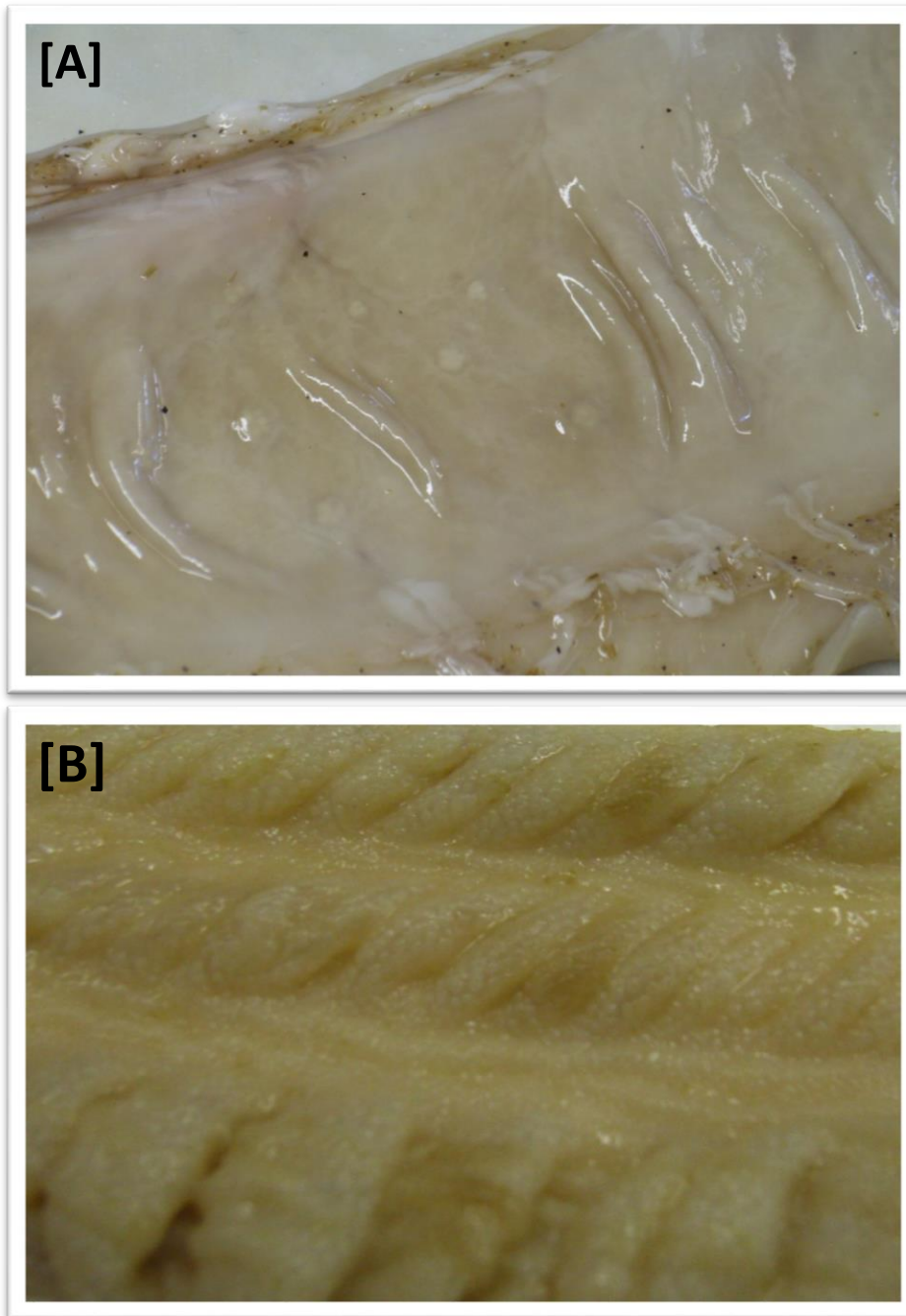
**Figure 5.** Total gastrointestinal fluid volumes in guinea pigs, rabbits and pigs (n=6 each, healthy males, fed *ad libitum*), normalized to [A] per Kg body weight and [B] per cm gut length.



**Figure 6.** Pig small intestinal section showing lymphoid follicles as a strip (collection of Peyer's patches)



**Figure 7.** Rabbit appendix fully covered with lymphoid follicles.



**Figure 8.** Lymphoid tissue in colon, [A] collection of lymphoid follicles in pig, [B] strip of lymphoid follicles in rabbit



## Conclusion

Significant inter-species differences were observed in the anatomy and physiology of the gut (pH profile, water content and distribution/number of lymphoid follicles) of the guinea pig, rabbit and the pig, which could lead to unrealistic expectations when these animal models are used in pre-clinical studies. The peculiar differences such as, the presence of well-defined caecum in the guinea pig, rabbit and pig in contrast to man, may have implications for orally administered formulations targeted to the colon. The differences in gastrointestinal pH, such as, a relatively low gastric pH in the rabbit and the lower pH in the pig small intestine, are important aspects for consideration, particularly for pH responsive formulations and ionisable drugs. The abundance of gastric lymphoid tissue in healthy pig reaffirms its utility in investigations related to diseased or infected stomach. Significant availability of lymphoid follicles in the small intestine and colon of the guinea pig, rabbit, and particularly the pig indicates their potential application in oral and colonic vaccination. The similarities and dissimilarities among the animal models and with the human gastrointestinal tract indicate that some animals may be suitable for specific studies related to particular parts of the gastrointestinal tract.

This article is published in *Eur J Pharm Sci* (2011) 42(1-2):3-10 doi: 10.1016/j.ejps.2010.09.019

The Published version of this article is available [here](#)